



Submental flap in head and neck reconstruction

Colgajo submentoniano en la reconstrucción de cabeza y cuello

Adonis Tupac Ramírez¹ , Manuel Latorre-Quintana² , Jeremías Carvajal³ 

- 1 MD, specialist in General Surgery and Head and Neck Surgery, Master in Clinical Epidemiology and in Education, Clínica San Rafael de Pereira, Universidad Tecnológica de Pereira; tutor, Head and Neck Surgery Interest Group; director, Salud Empática, Pereira, Colombia.
- 2 MD, Universidad Surcolombiana, Neiva, Colombia.
- 3 MD, academic director, SURCAC S.A.S.; member, Head and Neck Surgery Interest Group, Bogotá, Colombia.

Abstract

Introduction. Flaps from the territory of the submental artery can be used as a cutaneous, musculofacial and osteocutaneous flap, performing primary closure of the donor site defect, without generating major functional or aesthetic defects.

Methods. To describe the experience of the same surgical team, the complications related to the use of the flap and the oncological results, as well as the late outcomes during the follow-up of the patients included in the study.

Results. Twenty-one patients with a mean age of 66 years (range: 52-86), with oncological pathology of the tongue, lower lip, soft palate, nose, orbit, and oropharynx were included. All patients underwent ipsilateral selective neck dissection after flap removal, and in all cases the marginal mandibular nerve was preserved. Complications such as partial necrosis were recorded. The mean hospital stay was 8 days.

Conclusions. The submental artery flap has shown favorable results due to its versatile use, wide arc of rotation, color, and low donor site morbidity. More robust studies are recommended, including the experience of various specialists in countries sharing the same technical limitations and sociodemographic characteristics.

Keywords: head and neck neoplasms; myocutaneous flap; autologous transplantation; tissue transplantation; postoperative period.

Received: 10/30/2021 - Accepted: 04/21/2022 - Published online: 06/28/2022

Corresponding author: Adonis Tupac Ramírez, calle 7 # 18-107 Casa 1, Pereira, Colombia. Tel.: 3203393506.

Email: adonistupac@gmail.com

Citar como: Ramírez-Cuellar AT, Sánchez-Jiménez W, Latorre-Quintana M. Colgajo submentoniano en la reconstrucción de cabeza y cuello. Rev Colomb Cir. 2022;37:580-7. <https://doi.org/10.30944/20117582.1872>

This is an open Access under a Creative Commons License - BY-NC-ND <https://creativecommons.org/licenses/by-ncnd/4.0/deed.es>

Resumen

Introducción. Los colgajos del territorio de la arteria submentoniana pueden ser utilizados como un colgajo cutáneo, musculofacial y osteocutáneo, realizando cierres primarios del defecto del sitio donante, sin generar defectos funcionales ni estéticos mayores.

Métodos. Describir la experiencia de nuestro equipo quirúrgico, las complicaciones relacionadas con el uso del colgajo y los resultados oncológicos, así como los desenlaces tardíos durante el seguimiento de los pacientes incluidos en el estudio.

Resultados. Se incluyeron veintiún pacientes, con una edad media de 66 años (rango 52 - 86), con patología oncológica de lengua, labio inferior, paladar blando, nariz, órbita y orofaringe. Todos los pacientes fueron sometidos a disección selectiva ipsilateral del cuello, tras la extracción del colgajo y en todos los casos se preservó el nervio mandibular marginal. Se registraron complicaciones como la necrosis parcial. La estancia hospitalaria media fue de 8 días.

Conclusiones. El colgajo de la arteria submentoniana ha mostrado resultados favorables debido a su uso versátil, amplio arco de rotación, color y baja morbilidad del sitio donante. Se recomienda realizar estudios más robustos, que incluyan la experiencia de diversos especialistas en países que compartan las mismas limitaciones técnicas y características sociodemográficas.

Palabras clave: neoplasias de cabeza y cuello; colgajo miocutáneo; trasplante autólogo; trasplante de tejidos; período posoperatorio.

Introduction

Squamous cell carcinoma of the oral cavity represents the sixth most common type of cancer in the world, normally affected between 50 and 60 years of age¹⁻³. This type of injury can damage the floor of the mouth, the cheeks and the inner surface of the lip, with the tongue being the most affected site⁴.

The reconstruction of soft tissue defects in the oral cavity represents a complex surgical situation and a technical challenge for specialists in head and neck surgery, for which the use of microvascular free flaps has been considered the best therapeutic option. However, for medical service providers they are high cost, given the requirement of a group with surgical experience, long surgical times, and prolonged hospital stays.

In centers with limited experience and little access to microsurgical reconstruction techniques, pedicle flaps continue to be the fundamental tool in reconstructive head and neck surgery, although they have some limitations, such as unpredictable viability and limited mobility.

The submental artery territory flap (SATF) was initially described by Martin in 1933, docu-

menting a reconstruction of facial defects, as an alternative to free flaps, due to its color, shape, and texture⁵. Three years later, Sterne⁶ described the use of SATF for oncologic reconstruction of the oral cavity after ablative surgery. In the last three years, these flaps have proven to be a reliable option in head and neck reconstruction surgery⁷, despite the risk due to the possible compromise of cervical lymph node chains⁸.

The submental artery originates as a collateral branch of the facial artery, traveling deep to the anterior belly of the digastric muscle in 70% of patients or superficial in 30% of patients, and ends behind the mandibular symphysis⁹. Along their course, the cutaneous perforators traverse the platysma and the anterior belly of the digastric muscle, thus constructing a subdermal plexus that forms an anastomotic network with the contralateral artery. Regarding venous drainage, it is carried out by the submental branch that drains to the facial, communicating with the external and internal jugular veins^{10,11}.

The flaps of the territory of the submental artery have a long pedicle (8 cm), consistent, reliable, and characterized by dimensions that can

reach up to 6x12 cm. In addition, the SATF can be used as a cutaneous, musculofacial and osteocutaneous flap, performing the primary closure of the donor site defect without causing major functional or aesthetic defects¹².

This study aimed to share the experience with the SATF of the same surgical team, describe the complications related to the use of the flap and the oncological results, as well as the late outcomes during the follow-up of the patients included in the study.

Methods

Observational, descriptive, and retrospective clinical study. The study included patients diagnosed with squamous cell carcinoma of the oral cavity, stages I and II according to the criteria of the Union Internationale Contre le Cancer (UICC) and the American Joint Committee on Cancer (AJCC) 7th edition, without previous treatment, with clinical and radiological cervical classification N0, who were candidates for surgery. The surgical technique used was a standard SATF (Figure 1), previously described in the literature by other authors¹³.

A descriptive statistical analysis was performed using STATA software (Stata Corporation, College Station, Texas) version 14 SE. For the quantitative variables, measures of central tendency (means) and dispersion (standard deviation)

were used, after verifying the normality of their distribution by means of a Shapiro-Wilk test; if this assumption was not verified, they were described by means of median and interquartile ranges.

Results

We included 21 subjects who required ablative surgery with reconstruction with SATF between January 2016 and January 2021. They were 12 men (57.1%) and nine women (42.8%), with a mean age of 66.7 ± 14 years (range: 52 - 86) (Table 1).

The tumor was located in the tongue in 16 patients (76.2%) and in the lower lip, soft palate, nose (Figure 2), orbit and oropharynx, in one subject at each site. All patients underwent selective ipsilateral neck dissection after flap extraction, and in all cases the marginal mandibular nerve was preserved. One patient (4.8%) presented partial necrosis of the flap as a postoperative complication.

The mean hospital stay was 8 ± 11 days (range: 6 - 23) and the mean postoperative follow-up was 12 months. No patient developed local or regional recurrence during follow-up. During the late postoperative period, 17 patients were alive and two died, one of them due to an acute myocardial infarction and the other due to an iliofemoral bypass rupture.

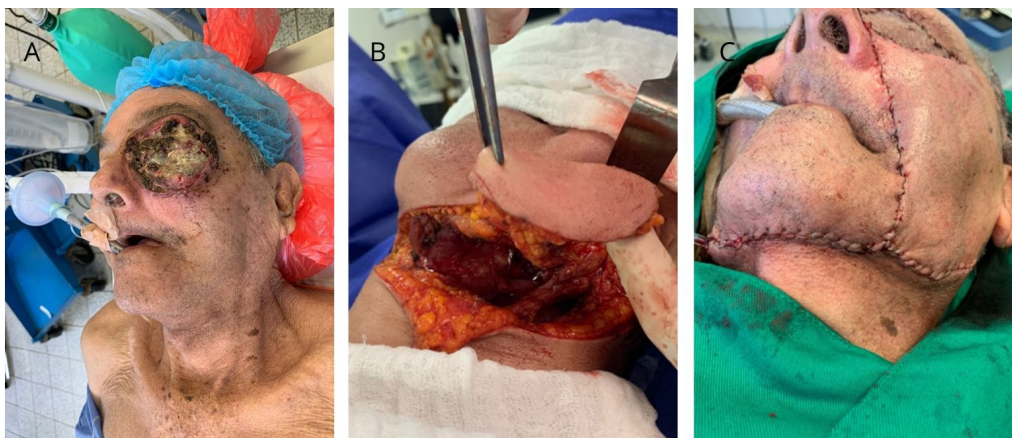


Figure 1. Reconstruction in a patient with an injury to the orbital cavity. A) Intraoperative evaluation of the lesion. B) Reconstruction with submental flap. C) Assessment in the immediate postoperative period. Source: the authors.

Table 1. Characterization of patients operated on for oral cavity cancer (n=21).

Variable	Frequency (%)
Age (years)	
Range	52 - 86
Mean (Standard deviation)	66.7 (14)
Sex	
Male	12 (57.1)
Location of the lesion	
Tongue	16 (76.2)
Palate	1 (4.8)
Nose	1 (4.8)
Lips	1 (4.8)
Oropharynx	1 (4.8)
Orbit	1 (4.8)
Complications	
Partial flap necrosis	1 (4.8)
Mortality in the immediate postoperative period	0

Source: the authors.

Discussion

The use of free flaps has been accepted as the first option for the reconstruction of residual defects after ablative oncological surgery due to neoplasms in the oral cavity^{14,15}. However, its use is not recommended in patients with diseases that contraindicate the performance of surgical procedures (such as a high American Society of Anesthesiology - ASA score), or with few vessels in the neck as a result of previous medical or surgical procedures. It should also be considered that surgical times are longer compared to the submental flap, impacting hospital stay, costs, and immediate postoperative complications^{16,17}.

The use of pedunculated myocutaneous flaps, such as the pectoralis major flap, is another excellent surgical option, characterized by its technical simplicity and good blood supply^{18,19}, but the disadvantages of these flaps must be considered, such as the large volume, the secondary surgical revision and significant rates of complications, especially in female patients^{20,21}.

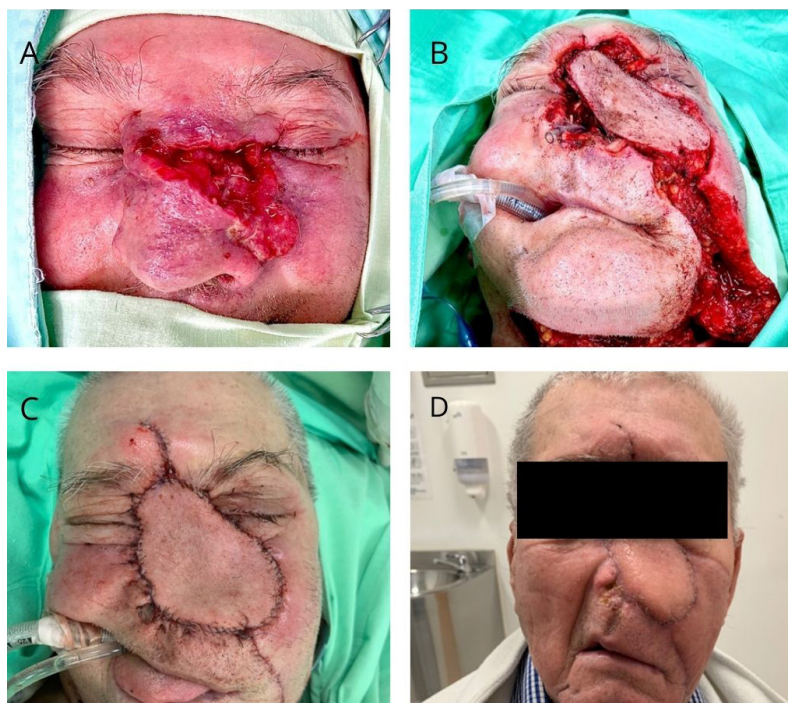

Figure 2. Standard SATF surgical technique. A) Intraoperative evaluation of the skin lesion on the back and nasal bridge. B) Reconstruction of defects with the standard SATF technique. C) Assessment in the immediate postoperative period. D) Evaluation in the late postoperative period. Source: the authors.

The SATF is based on the submental artery, a collateral branch of the facial artery, which originates from the external carotid artery and allows an anastomosis in 92% of cases with the contralateral artery²². It is located medially, on the lower border of the mandible²³, which allows blood to be supplied to the floor of the mouth in 60% of cases²⁴. With our experience, we have documented that the flap has a long pedicle, with a wide arc of rotation, which allows it to cover a large surface of the operated area. This flap is an ideal substitute for defects in the oral cavity or facial region, considering the similarity in texture and the ability to close the donor site with minimal aesthetic sequelae.

Therefore, SATF is recognized as a reliable alternative to microvascular free flaps, especially in the elderly population or with risks due to severe comorbidities such as malnutrition, difficult-to-manage pathologies or life-threatening conditions, which makes these patients not suitable candidates for prolonged microvascular surgery, where less aggressive treatments are required, with reduced surgical times, particularly for the management of small defects^{7,26,27}.

The SATF can be used in several ways, the best known being the myocutaneous, fasciocutaneous, osteocutaneous or cutaneous flap²⁸, commonly used in the lower, middle and upper part of the face, for malar augmentation with fascia flap^{26,29}, in the reconstruction of hairy skin defects³⁰, in defects of the tongue, floor of the mouth, oral mucosa, neopharynx or palatines³¹, in nasal³², lip³³⁻³⁵, or cervical esophagus³⁶⁻³⁸ reconstruction, in the repair of defects due to hemilaryngectomy²⁸, total laryngectomy or fistulas pharyngocutaneous^{39,40}.

In the literature, there is still controversy about the oncological safety of SATF due to the relationship between the flap and the lymph nodes of region I-B, because these lymph node levels could be compromised even in an early stage of oral cavity cancer^{41,42}, increasing the risk of recurrence^{41,43,44}, as well as challenging the performance of a rigorous level I cervical lymph node dissection. Some authors state that the submental flap should be avoided if there is any

suspicion of level I involvement⁷. Additionally, they have warned about the potential risk of this flap in patients with clinical or radiological evidence of cervical metastases at level I. Among the most important recommendations, dissection in the subplatysmal plane is contemplated to minimize the possibilities of tumor dissemination and inadequate dissection⁴⁵.

The technique for performing the flap may vary according to the validated literature, considering that the inclusion of the anterior belly of the digastric muscle in the flap has been controversial. For the present study, the anterior belly of the digastric muscle was included to improve blood supply, however, it should be emphasized that the use of this flap is contraindicated in patients with a history of neck dissection to guarantee the success of this technique, given that the integrity of the facial artery and vein is required.

The use of color Doppler ultrasound in the location of the facial artery, veins and perforators can drastically reduce the failure rate of the technique⁴⁶, thus reducing complications, as in this series of patients, in which a case of partial necrosis of the flap was documented. Another known complication is marginal mandibular nerve injury during SATF, reported in 0% to 17%. To reduce this risk, the literature recommends identification of the nerve before raising the flap⁶. In our experience, only one patient developed a transient marginal mandibular nerve palsy.

As limitations of the present study, the experience in a significant group of patients based on a retrospective analysis of the variables of interest is described, for which it is recommended to carry out studies with a larger number of patients, a long follow-up period and to include the experience of more specialized centers, thus generating results with greater validity and application.

Conclusion

The submental artery territory flap has shown promising results due to its versatile use, wide arc of rotation, color and low donor site morbidity, and although there are some controversies about oncological safety, it could be a useful tool in the reconstruction of head and neck in well-selected

patients. More robust studies are recommended, including the experience of various specialists in countries that share the same technical limitations and sociodemographic characteristics.

Compliance with ethical standards

Informed consent: The research presented here is classified as minimal risk according to Resolution 008430 of October 4, 1993 issued by the Ministry of Health of Colombia; likewise, no informed consent was given since it is a retrospective collection of information from medical records that does not directly involve subjects in any specific activity during the investigation. This research was approved by the Institutional Ethics Committee of the participating institutions, in order to protect the rights, dignity and well-being of the patients included in the study.

Conflict of interest: none declared by the authors.

Funding: no external funding was received.

Author's contributions:

- Conception and design of the study: Wanda Sánchez-Jiménez.
- Acquisition of data: Adonis Tupac Ramírez-Cuellar.
- Data analysis and interpretation: Manuel Latorre-Quintana.
- Drafting the manuscript: Wanda Sánchez-Jiménez, Manuel Latorre-Quintana.
- Critical review: Adonis Tupac Ramírez-Cuellar.

References

1. Jemal A, Siegel R, Ward E, Murray T, Xu J, Smigal C, Thun MJ. Cancer statistics, 2006. *CA Cancer J Clin.* 2006;56:106-30. <https://doi.org/10.3322/canjclin.56.2.106>
2. Kerawala C, Roques T, Jeannon JP, Bisase B. Oral cavity and lip cancer: United Kingdom National Multidisciplinary Guidelines. *J Laryngol Otol.* 2016;130(Suppl 2):S83-S89. <https://doi.org/10.1017/S0022215116000499>
3. de Vicente JC, de Villalain L, Torre A, Peña I. Microvascular free tissue transfer for tongue reconstruction after hemiglossectomy: A functional assessment of radial forearm versus anterolateral thigh flap. *J Oral Maxillofac Surg.* 2008;66:2270-5. <https://doi.org/10.1016/j.joms.2008.01.018>
4. Veness MJ, Morgan GJ, Sathiyaseelan Y, Gebiski V. Anterior tongue cancer and the incidence of cervical lymph node metastases with increasing tumour thickness: should elective treatment to the neck be standard practice in all patients? *ANZ J Surg.* 2005;75:101-5. <https://doi.org/10.1111/j.1445-2197.2005.03306.x>
5. Martin D, Pascal JF, Baudet J, Mondie JM, Farhat JB, Athoum A, et al. The submental island flap: a new donor site. Anatomy and clinical applications as a free or pedicled flap. *Plast Reconstr Surg.* 1993;92:867-73.
6. Sterne GD, Januszkiewicz JS, Hall PN, Bardsley AF. The submental island flap. *Br J Plast Surg.* 1996;49:85-9. [https://doi.org/10.1016/s0007-1226\(96\)90078-8](https://doi.org/10.1016/s0007-1226(96)90078-8)
7. Sebastian P, Thomas S, Varghese BT, Iype EM, Balagopal PG, Mathew PC. The submental island flap for reconstruction of intraoral defects in oral cancer patients. *Oral Oncol.* 2008;44:1014-8. <https://doi.org/10.1016/j.oraloncology.2008.02.013>
8. Cariati P, Cabello-Serrano A, Marin-Fernandez AB, Perez de Perceval-Tara M, Juliá MA, Martínez-Lara MI. Is submental flap safe for the oncological reconstruction of the oral cavity? *J Stomatol Oral Maxillofac Surg.* 2018;119:284-7. <https://doi.org/10.1016/j.jormas.2018.06.006>
9. Patel UA, Bayles SW, Hayden RE. The submental flap: A modified technique for resident training. *Laryngoscope.* 2007;117:186-9. <https://doi.org/10.1097/01.mlg.0000246519.77156.a4>
10. Potter S, De Blacam C, Kosutic D. True submental artery perforator flap for total soft-tissue chin reconstruction. *Microsurgery.* 2012;32:502-4. <https://doi.org/10.1002/micr.21983>
11. Matsui A, Lee BT, Winer JH, Laurence RG, Frangioni JV. Submental perforator flap design with a near-infrared fluorescence imaging system: The relationship among number of perforators, flap perfusion, and venous drainage. *Plast Reconstr Surg.* 2009;124:1098-1104. <https://doi.org/10.1097/PRS.0b013e3181b5a44c>
12. Sittitrai P, Srivanitchapoom C, Reunmakkaew D, Yata K. Submental island flap reconstruction in oral cavity cancer patients with level I lymph node metastasis. *Br J Oral Maxillofac Surg.* 2017;55:251-5. <https://doi.org/10.1016/j.bjoms.2016.10.022>
13. Schonauer F, Di Martino A, Nele G, Santoro M, Dell'Aversana Orabona G, Califano L. Submental flap as an alternative to microsurgical flap in intraoral post-oncological reconstruction in the elderly. *Int J Surg.* 2016;33(Suppl 1):51-6. <https://doi.org/10.1016/j.ijisu.2016.05.051>
14. Cinar C, Ogur S, Arslan H, Kilic A. Adding versatility to the reconstruction of intraoral lining: opened pocket method. *J Craniofac Surg.* 2007;18:198-202. <https://doi.org/10.1097/01.scs.0000249356.66720.9b>
15. Valentini V, Saltarel A, Cassoni A, Battisti A, Egidi S. One-stage reconstruction of a defect of the oral commissure and of the cheek with a radial forearm free flap. *J Craniofac Surg.* 2008;19:1508-11. <https://doi.org/10.1097/SCS.0b013e318175f3df>

16. Kesting MR, Hölzle F, Wales C, Steinstraesser L, Wagenpfeil S, Mücke T, et al. Microsurgical reconstruction of the oral cavity with free flaps from the anterolateral thigh and the radial forearm: A comparison of perioperative data from 161 cases. *Ann Surg Oncol*. 2011;18:1988-94. <https://doi.org/10.1245/s10434-011-1584-8>
17. Paydarfar JA, Patel UA. Submental island pedicled flap vs radial forearm free flap for oral reconstruction: Comparison of outcomes. *Arch Otolaryngol Head Neck Surg*. 2011;137:82-7. <https://doi.org/10.1001/archoto.2010.204>
18. Metgudmath RB, Metgudmath AR, Metgudmath VV, Roy B, Das AT. Versatility of pectoralis major myocutaneous flap in oncology and its role in developing countries. *Indian J Otolaryngol Head Neck Surg*. 2013;65(Suppl 1):80-4. <https://doi.org/10.1007/s12070-012-0535-4>
19. McLean JN, Carlson GW, Losken A. The pectoralis major myocutaneous flap revisited: A reliable technique for head and neck reconstruction. *Ann Plast Surg*. 2010;64:570-3. <https://doi.org/10.1097/SAP.0b013e3181c51f4a>
20. Mehrhof AI, Rosenstock A, Neifeld JP, Merritt WH, Theogaraj SD, Cohen IK. The pectoralis major myocutaneous flap in head and neck reconstruction. Analysis of complications. *Am J Surg*. 1983;146:478-82. [https://doi.org/10.1016/0002-9610\(83\)90235-0](https://doi.org/10.1016/0002-9610(83)90235-0)
21. El-Marakby HH. The reliability of pectoralis major myocutaneous flap in head and neck reconstruction. *J Egypt Natl Canc Inst*. 2006;18:41-50.
22. Magden O, Edizer M, Tayfur V, Atabey A. Anatomic study of the vasculature of the submental artery flap. *Plast Reconstr Surg*. 2004;114:1719-23. <https://doi.org/10.1097/01.prs.0000142479.52061.7d>
23. Kim DH, Won SY, Choi DY, Kim HS, Jung UW, Kim HJ, Hu KS. Topography of the submental artery that should be considered in bleeding during dentoalveolar surgery. *J Craniofac Surg*. 2012;23:1453-6. <https://doi.org/10.1097/SCS.0b013e31824e6d48>
24. Bavitz JB, Harn SD, Homze EJ. Arterial supply to the floor of the mouth and lingual gingiva. *Oral Surg Oral Med Oral Pathol*. 1994;77:232-5. [https://doi.org/10.1016/0030-4220\(94\)90290-9](https://doi.org/10.1016/0030-4220(94)90290-9)
25. Lee JC, Lai WS, Kao CH, Hsu CH, Chu YH, Lin YS. Multiple-parameter evaluation demonstrates low donor-site morbidity after submental flap harvesting. *J Oral Maxillofac Surg*. 2013;71:1800-8. <https://doi.org/10.1016/j.joms.2013.03.018>
26. Chen WL, Li JS, Yang ZH, Huang ZQ, Wang JU, Zhang B. Two submental island flaps for reconstructing oral and maxillofacial defects following cancer ablation. *J Oral Maxillofac Surg*. 2008;66:1145-56. <https://doi.org/10.1016/j.joms.2007.09.023>
27. Behan FC, Rozen WM, Wilson J, Kapila S, Sizeland A, Findlay MW. The cervico-submental keystone island flap for locoregional head and neck reconstruction. *J Plast Reconstr Aesthet Surg*. 2013;66:23-8. <https://doi.org/10.1016/j.bjps.2012.08.027>
28. Vural E, Suen JY. The submental island flap in head and neck reconstruction. *Head Neck*. 2000;22:572-8. [https://doi.org/10.1002/1097-0347\(200009\)22:6<572::aid-hed5>3.0.co;2-k](https://doi.org/10.1002/1097-0347(200009)22:6<572::aid-hed5>3.0.co;2-k)
29. Tan O, Atik B, Parmaksizoglu D. Soft-tissue augmentation of the middle and lower face using the deepithelialized submental flap. *Plast Reconstr Surg*. 2007;119:873-9. <https://doi.org/10.1097/01.prs.0000252002.76466.cf>
30. Demir Z, Kurtay A, Şahin U, Velidedeoğlu H, Çelebioğlu S. Hair-bearing submental artery island flap for reconstruction of mustache and beard. *Plast Reconstr Surg*. 2003;112:423-9. <https://doi.org/10.1097/01.PRS.0000070520.96829.85>
31. Rahpeyma A, Khajehahmadi S, Nakhaei M. Submental artery island flap in reconstruction of hard palate after wide surgical resection of verrucous carcinoma, two case reports. *Iran J Otorhinolaryngol*. 2013;25:177-81.
32. Tan O, Kiroglu AF, Atik B, Yuca K. Reconstruction of the columella using the prefabricated reverse flow submental flap: A case report. *Head Neck*. 2006;28:653-7. <https://doi.org/10.1002/hed.20395>
33. Kitazawa T, Harashina T, Taira H, Takamatsu A. Bipedicled submental island flap for upper lip reconstruction. *Ann Plast Surg*. 1999;42:83-6. <https://doi.org/10.1097/00000637-199901000-00014>
34. Koshima I, Inagawa K, Urushibara K, Moriguchi T. Combined submental flap with toe web for reconstruction of the lip with oral commissure. *Br J Plast Surg*. 2000;53:616-9. <https://doi.org/10.1054/bjps.2000.3429>
35. Yilmaz M, Menderes A, Barutçu A. Submental artery island flap for reconstruction of the lower and mid face. *Ann Plast Surg*. 1997;39:30-5. <https://doi.org/10.1097/00000637-199707000-00005>
36. Janssen DA, Thimsen DA. The extended submental island lip flap: an alternative for esophageal repair. *Plast Reconstr Surg*. 1998;102:835-8. <https://doi.org/10.1097/00006534-199809030-00034>
37. Zhang B, Wang JG, Chen WL, Yang ZH, Huang ZQ. Reverse facial-submental artery island flap for reconstruction of oropharyngeal defects following middle and advanced-stage carcinoma ablation. *Br J Oral Maxillofac Surg*. 2011;49:194-7. <https://doi.org/10.1016/j.bjoms.2010.04.009>
38. Wang WH, Hwang TZ, Chang CH, Lin YC. Reconstruction of pharyngeal defects with a submental island flap after hypopharyngeal carcinoma ablation. *ORL J Otorhinolaryngol Relat Spec*. 2012;74:304-9. <https://doi.org/10.1159/000345100>
39. Demir Z, Velidedeoğlu H, Çelebioğlu S. Repair of pharyngocutaneous fistulas with the submental artery island flap. *Plast Reconstr Surg*. 2005;115:38-44.
40. Abboud O, Shedid D, Ayad T. Reconstruction of the prevertebral space with a submental flap: A novel application. *J Plast Reconstr Aesthet Surg*. 2013;66:1763-5. <https://doi.org/10.1016/j.bjps.2013.04.036>

41. Parmar PS, Goldstein DP. The submental island flap in head and neck reconstruction. *Curr Opin Otolaryngol Head Neck Surg.* 2009;17:263-6. <https://doi.org/10.1097/M00.0b013e32832cee83>
42. Elzahaby IA, Roshdy S, Shahatto F, Hussein O. The adequacy of lymph node harvest in concomitant neck block dissection and submental island flap reconstruction for oral squamous cell carcinoma; a case series from a single Egyptian institution. *BMC Oral Health.* 2015;15:80. <https://doi.org/10.1186/s12903-015-0064-0>
43. Amin AA, Sakkary MA, Khalil AA, Rifaat MA, Zayed SB. The submental flap for oral cavity reconstruction: Extended indications and technical refinements. *Head Neck Oncol.* 2011;3:51. <https://doi.org/10.1186/1758-3284-3-51>
44. Cheng MH, Lin CY, Patel KM. A prospective clinical assessment of anatomic variability of the submental vascularized lymph node flap. *J Surg Oncol.* 2017;115:43-7. <https://doi.org/10.1002/jso.24487>
45. Chow TL, Chan TT, Chow TK, Fung SC, Lam SH. Reconstruction with submental flap for aggressive orofacial cancer. *Plast Reconstr Surg.* 2007;120:431-6. <https://doi.org/10.1097/01.prs.0000267343.10982.dc>
46. Yamauchi M, Yotsuyanagi T, Ezoe K, Saito T, Ikeda K, Arai K. Reverse facial artery flap from the submental region. *J Plast Reconstr Aesthet Surg.* 2010;63:583-8. <https://doi.org/10.1016/j.bjps.2009.01.035>