









# Stent utilization in benign colorectal stenosis

## Uso de stent en estenosis colorrectal benigna

Rodrigo Castaño-Llano<sup>1</sup> , Natalia Guzmán-Arango<sup>2</sup> , Pablo Posada-Moreno<sup>3</sup> ,  
Romario Chanci-Drago<sup>3</sup> , Juan Darío Puerta-Díaz<sup>4</sup> , Isabella Cadavid-Agudelo<sup>5</sup> ,  
Juan Esteban Puerta-Botero<sup>5</sup> , Oscar Álvarez-Barrera<sup>6</sup> 

- 1 MD, specialist in General Surgery and Gastrointestinal and Endoscopy, Instituto de Cancerología, Clínica Las Américas Auna, Medellín, Colombia.
- 2 MD, specialist in Epidemiology, resident of General Surgery, Universidad Pontificia Bolivariana, Medellín, Colombia.
- 3 MD, resident of General Surgery, Universidad Pontificia Bolivariana, Medellín, Colombia.
- 4 MD, specialist in General and Colorectal Surgery, Clínica Las Américas Auna, Medellín, Colombia.
- 5 Medical student, Universidad CES, Medellín, Colombia.
- 6 MD, specialist in Internal Medicine, Gastroenterology and Radiology, Texas Digestive Specialists, McAllen, USA.

### Abstract

**Introduction.** Benign colorectal stenosis refers to an anatomical condition characterized by a decrease in the diameter of the intestinal lumen distal to the ileocecal valve, which might cause a series of obstructive signs and symptoms. It is a rare entity, caused in the vast majority of cases due to intestinal anastomosis at the described level. The purpose of this study is to determine the performance of colonic stents in the management of non-malignant colorectal strictures.

**Methods.** Descriptive study of a cohort of patients who developed colonoscopy-confirmed benign colorectal stenosis in three high-complexity hospitals in the city of Medellín, Colombia, between 2007 and 2021.

**Results.** Thirty-four patients diagnosed with benign colorectal stenosis managed with self-expanding metal stents were included in the study. Median follow-up was 19 months, obtaining clinical success in 73.5% of cases, with a complication rate of 41.2%, mainly due to reobstruction and migration of the stent, and to a lesser extent due to perforation secondary to device placement.

**Conclusion.** Self-expanding metallic stents represent a therapeutic option in patients with colorectal obstruction caused by non-malignant stenosing pathology. When diversion through a stoma is not an option, this type of device is associated with high rates of clinical success and improvement in the patients' quality of life.

**Keywords:** colon; rectum; rectal diseases; pathologic constriction; self-expandable metallic stents; surgical anastomosis.

Received: 10/22/2022 - Accepted: 11/5/2022 - Published online: 1/21/2023

Corresponding author: Natalia Guzmán-Arango, Calle 3 # 25-299, Altos del tesoro Casa 107. Tel.: +57 3128964846.

Email: nataliaguzman9415@gmail.com

Cite as: Castaño-Llano R, Guzmán-Arango N, Posada-Moreno P, Chanci-Drago R, Puerta-Díaz JD, Cadavid-Agudelo I, Puerta-Botero JE, Álvarez-Barrera O. Uso de stent en estenosis colorrectal benigna. Rev Colomb Cir. 2023;38:268-74. https://doi.org/10.30944/20117582.2279.

This is an open Access under a Creative Commons License - BY-NC-ND https://creativecommons.org/licenses/by-ncnd/4.0/deed.es

## Resumen

**Introducción.** La estenosis colorrectal benigna hace referencia a una condición anatómica caracterizada por una disminución del diámetro de la luz intestinal distal a la válvula ileocecal, condicionando una serie de signos y síntomas de tipo obstructivo. Es una entidad poco frecuente, secundaria en la gran mayoría de veces a la realización de anastomosis intestinales al nivel descrito. El objetivo de esta investigación fue determinar la utilidad del *stent* colónico en estenosis secundaria a patología colorrectal no neoplásica.

**Métodos.** Estudio descriptivo de una cohorte de pacientes que desarrolló estenosis colorrectal de origen benigna confirmada por colonoscopia, en 3 hospitales de alta complejidad de la ciudad de Medellín, Colombia, entre los años 2007 y 2021.

**Resultados.** Se incluyeron 34 pacientes con diagnóstico de estenosis colorrectal de origen benigno, manejados con *stents* metálicos autoexpandibles. La mediana de seguimiento fue de 19 meses y se obtuvo éxito clínico en el 73,5 % de los casos. La tasa de complicación fue del 41,2 %, dada principalmente por reobstrucción y migración del *stent*, y en menor medida por perforación secundaria a la colocación del dispositivo.

**Conclusión.** Los *stents* metálicos autoexpandibles representan una opción terapéutica en pacientes con obstrucción colorrectal, con altas tasas de mejoría clínica en pacientes con patología estenosante no maligna. Cuando la derivación por medio de estoma no es una opción, este tipo de dispositivos están asociados a altas tasas de éxito clínico y mejoría de la calidad de vida de los pacientes.

**Palabras clave:** colon; recto; enfermedades del recto; constricción patológica; *stents* metálicos autoexpandibles; anastomosis quirúrgica.

## Introduction

Benign colorectal stenosis is a rare entity, with a great impact on the quality of life of those who suffer from it. It is defined as an abnormal narrowing of the distal gastrointestinal tract, which generates a series of signs and symptoms, and prevents the normal passage of the colonoscope, endoscope, or rigid sigmoidoscope.

It is generally secondary to various pathologies of the digestive tract, such as acute diverticulitis (especially those patients who present recurrent episodes), ischemic colitis, radiotherapy, inflammatory bowel disease (Crohn's disease), colorectal resections or extensive endoscopic mucosectomies, but it can also be associated with gynecological pathologies, such as endometriosis. A history of colorectal anastomosis is the most frequent cause of benign colorectal stenosis<sup>2</sup>.

The symptoms are variable and will generally be determined by the degree and extension of the stenosis, with abdominal pain, constipation and abdominal distension being the main symptoms<sup>2</sup>.

Multiple therapeutic options have been proposed for its management, from surgery to less invasive endoscopic management, whose options will vary depending on the site (colonic or rectal), the length, and the cause of the stenosis. For distal rectal stenosis, digital or endoscopic dilation, using Hegar dilators, balloons, and rectosigmoidoscopes of different diameters, have achieved good results<sup>2</sup>.

For colonic stenosis, the use of balloon dilation techniques has proven to be effective, associated or not with the use of corticosteroids<sup>3,4</sup>. Likewise, electrosurgery techniques with radial incision of the stenosis have had good results, especially in those short stenosis of less than one centimeter, mainly fibrotic<sup>5</sup>.

Regarding the use of stents for the management of colorectal strictures, most of the information available is derived from studies in cancer patients, with the use of stents for the management of benign strictures being a controversial issue, given the lack of evidence in this regard and the risk of failure in the handling and migration of the

stent reported in some works. However, the use of these devices could play an important role in benign stenosis, sometimes refractory to management with other endoscopic techniques, especially when associated with fistula<sup>6-8</sup>.

These colonic stents come in two forms, coated and uncoated. The main difference between them is that the coated ones (silicone, polyurethane, polytetraethylene) are easily removable, contrary to what happens with uncoated stents.

The objective of this study was to determine the usefulness of the covered and self-expanding colonic stent in patients with colorectal intraluminal non-neoplastic pathology, in a cohort of patients in 3 hospitals in Medellín, Colombia, between 2007 and 2021.

## Methods

A retrospective descriptive study was designed, with prospective follow-up, of a cohort of patients over 18 years of age who underwent stent placement in the colon or rectum, in 3 hospitals in the city of Medellín, Colombia, between January 2007 and December 2021.

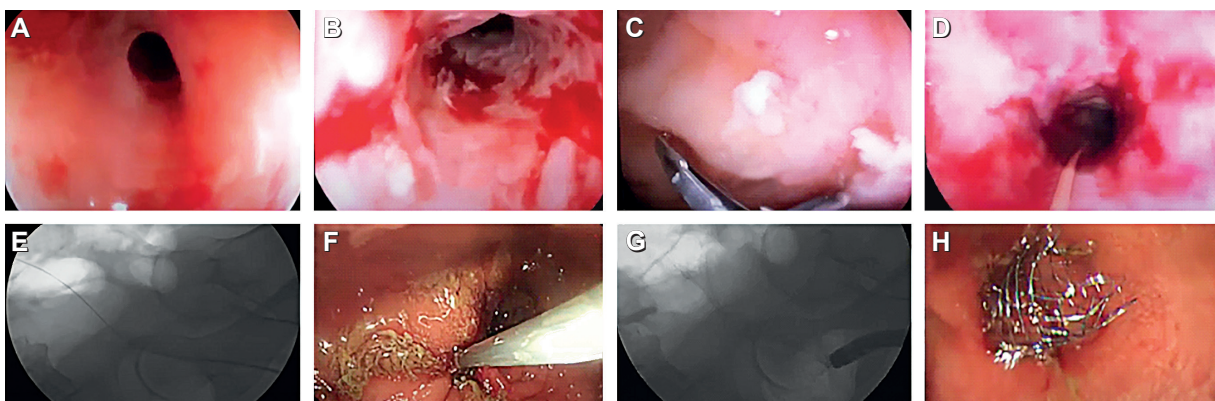
The inclusion criteria were: (a) non-neoplastic disease of the colon, (b) diagnosis of stenosis of the lumen confirmed by colonoscopy (it does not allow the passage of the colonoscope through the stenosis), and (c) placement of a covered, metallic

and self-contained stent. expandable. The causes of the obstructive process were divided into: (a) intraluminal stenosis with or without post-surgical fistula, (b) extrinsic compression, (c) intrinsic stenosis due to Crohn's disease, and (d) stenosis due to radiotherapy.

The indication for stent placement in colorectal stenosis was the development of gastrointestinal symptoms related to intestinal obstruction, manifested as pain, nausea, vomiting, or abdominal distension, with a high risk of complete occlusion of the intestinal lumen. The evaluation of the length and the proximal and distal limits of the stenotic segment was achieved under direct visualization in some patients, but in the majority by previous imaging studies.

The procedure was performed colonoscopically. The patients did not undergo colonic preparation due to the high risk of perforation and were managed with a rectal enema the night before the procedure and one hour before it. Sedation and analgesia were administered during the procedure, and prophylactic antibiotics were not used.

When the distal opening of the stenosis was identified by colonoscopy, a hydrophilic guidewire (Jagwire<sup>®</sup>, Terumo<sup>®</sup>) was inserted through the hole to advance the stent. The stents used were manufactured from nitinol with a metallic body, with a silicone or polyurethane cover and with



**Figure 1.** A. Stenosis of the colo-colonic anastomosis in a patient with Crohn's disease. B. After several failed sessions of balloon dilation. C. Taking biopsies to rule out malignancy. D. Passage of the guide wire through the not dilatable stricture. E. Fluoroscopic control of the guide wire passage. F. Passage of the stent through the stenosis. G. Fluoroscopic view of the stent release. H. Endoscopic appearance of the released stent.

self-expanding properties; the length ranged from 8 to 10 cm and the diameter from 22 to 24 mm (Boston Scientific®, Tecnostent®).

Technical success was defined as stent release in the position expected by the operator, and clinical success was documented by patient follow-up, defining a favorable clinical outcome as relief of obstructive signs or symptoms 72 hours after stent placement.

The information was obtained from primary sources in the cases in which the patients could be contacted, or secondary, through the review of the medical records. An estimation of absolute and relative frequencies was made for the qualitative variables, and measures of central tendency and dispersion for the quantitative variables. In addition, normality tests were performed to express the variables with a normal distribution, with mean and standard deviation; and non-normal, with median and interquartile range. Bivariate analysis was also carried out with the Chi-square test and multivariate analysis with a linear regression model.

## Results

Thirty-four patients with a diagnosis of colorectal stenosis of benign origin were included, with a similar distribution for all causes of stent placement. The median age was 68 years (IQR 56-72 years) and a little more than half were male (n=19, 55.9%).

The most frequent site of strictures was the rectum (n=15, 44.1%) (Table 1). Two patients with Crohn's disease presented strictures not

related to the anastomosis (terminal ileum and ileocecal valve), and one patient had extrinsic compression at the level of the transverse colon due to pancreatitis.

Most of the stent indications (n=24, 70.1%) were due to stricture of a previous anastomosis. Resection and anastomosis had been performed in 13 patients (38.2%) due to colorectal cancer, in nine patients due to diverticulitis (26.4%), and in two patients due to Crohn's disease (5.9%). According to the type of anastomosis performed, in 14 patients (41.1%) it was circular, in six (17.7%) latero-lateral with mechanical suture and in four (11.8%) latero-lateral with manual suture. In ten patients (29.4%) there was no history of anastomosis.

In eight of these 24 patients (23.5%), the stent was placed due to colonic stenosis associated with a fistula, five of which were secondary to intestinal resections for colorectal cancer, two secondary to diverticulitis, and one due to Crohn's disease.

The rest of the indications for stent placement were extrinsic compressions (n=6, 17.7%) secondary to gastric cancer (4 patients), pancreatic cancer (1) and pancreatitis (1), intrinsic stenosis due to Crohn's disease in two patients (5.9%) and after radiotherapy (as treatment for cervical cancer and bladder cancer) in two other patients (5.9%).

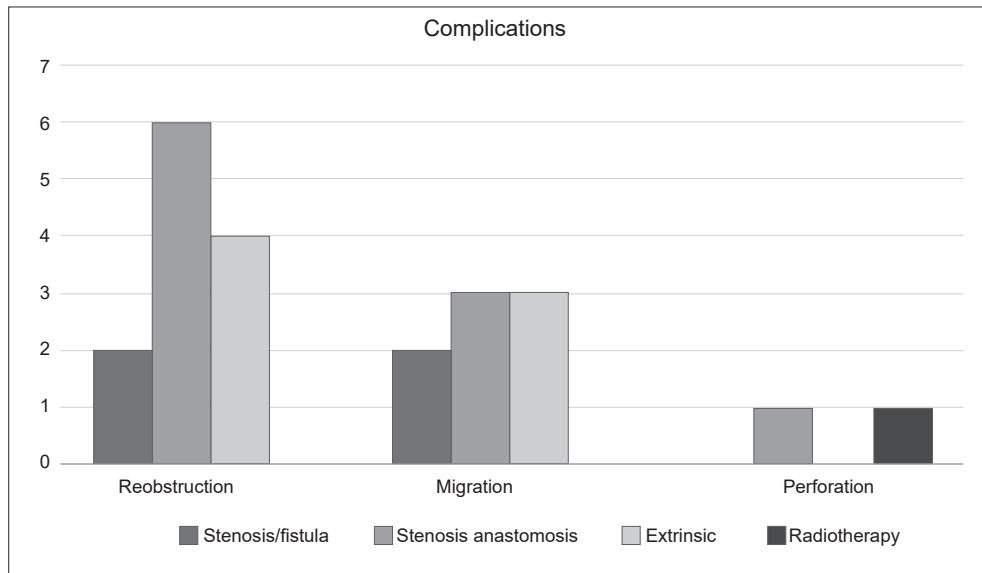
All patients had technical success. On the other hand, 25 (73.5%) of the 34 patients included in the study presented clinical success, 12 belonging to the group of stenosis of the anastomosis without fistula (n=12/16), six with stenosis associated with fistula (n =6/8), three with extrinsic compression (n=3/6), two patients with Crohn's disease and two patients with post-radiotherapy stenosis, without statistically significant differences. There was also no evidence of an association between clinical success and the underlying etiology or location of the stenosis.

In 14 patients (41.2%) some type of subsequent event occurred. The most common was re-obstruction in 12 patients (35.3%), followed by stent migration in eight patients (23.5%) and perforation in two patients (5.9%) (Figure 2). It was identified that in eight of the 12 patients who re-obstructed, it was due to migration of the

**Table 1.** Location of colonic stenosis.

Anatomical site	Frequency	%
Rectum	15	44.1
Sigmoid colon	10	29.4
Rectosigmoid junction	6	17.7
Terminal ileum	1	2.9
Ileocecal valve	1	2.9
Transverse colon	1	2.9

Source: Own authors.



**Figure 2.** Adverse outcomes by cause of stent placement. Source: Own authors.

colonic stent and, although the majority of re-obstructions ( $n=5$ , 41%) occurred in patients with circular anastomoses, no statistically significant association was found. None of the complications was associated with the location of the stenosis or the underlying etiology.

Two of the eight patients with an indication for colonic stenting due to stenosis associated with a fistula presented re-obstruction due to migration and none was perforated. Of the 16 patients with stricture of the anastomosis without a fistula, seven had an unfavorable outcome: six re-obstructions (three due to migrations) and one perforation. Most of this group of patients ( $n=9$ , 56.3%) had undergone a circular anastomosis, four mechanical side-to-side patients and three manual side-to-side for different etiologies. Of the six patients with extrinsic compressions, four were complicated by re-obstruction (three due to migration); there was no perforation. Finally, one of the two patients with stricture from radiotherapy perforated. No patient with obstruction due to Crohn's disease was complicated.

Median stent duration for all patients included in the study was 7 weeks (IQR 4-10 months),

and for those with clinical success 8 months (IQR 7-10), compared to a median of 2 months (IQR 1-3) in those without clinical success. Median overall follow-up was 19 months (IQR 12-26 months).

## Discussion

When the available information on the use of this type of stents for the management of colorectal stenosis of non-malignant origin is evaluated, the volume of published articles is small, and the evidence in this regard is scarce and of low quality, as described in the systematic review published by Manterola and Urrutia in 2014<sup>9</sup>, because the use of these devices in the context of benign stenosis is rare and there is still skepticism about their performance in non-neoplastic diseases<sup>10</sup>.

Self-expanding metallic stents have shown that in the context of malignant colorectal obstruction, short- and long-term results have been satisfactory, with an adequate clinical success rate, achieving good tolerance and improving the quality of life of patients<sup>11</sup>.

In the cohort of our patients with benign colorectal strictures, clinical success was achieved in 73.5% of cases, a percentage comparable to the



results of previous studies, where the success rate in the management of benign strictures, mainly those caused by colorectal anastomosis, it was from 63% to 80%<sup>6,12</sup>. On the other hand, failure rates of up to 60% have been reported in the literature<sup>12</sup>.

Currently, the use of covered stents is preferred, since in the event of any complication arising from their use, they can be removed more easily. However, it is important to take into account that in the long term, these silicone-coated stents may have a higher risk of causing complications derived from migration, causing obstruction<sup>11,12</sup>. In our study it was possible to observe that the rate of complications derived from the use of these devices is not negligible (41.2%), with reobstruction being mostly secondary to stent migration, a finding similar to that published by Caruso et al.<sup>13,14</sup>.

Most of the strictures occurred at the level of the rectum (44.1%), which is the anatomical site with the smallest diameter compared to other colonic segments and a location where circular-type anastomosis is often performed, due to technical difficulties in performing another type of anastomosis. Likewise, the percentage of obstruction was higher in circular anastomoses. However, no statistically significant association was found between the stricture site and clinical success. This leads us to question whether those patients with circular colorectal anastomoses could be at greater risk of presenting strictures and, therefore, could benefit more from the insertion of these devices.

Our work has important limitations. The main one is the retrospective nature of the study design, which only allowed us to carry out a descriptive exercise, therefore, it is not possible to make direct associations or issue recommendations regarding the use or not of these devices for the management of this pathology. Furthermore, the number of patients included in the study is limited.

## Conclusions

Self-expanding metallic stents represent a therapeutic option in patients with non-neoplastic colorectal obstruction. When stoma diversion is not an option, these types of devices are associa-

ted with high clinical success rates and improved quality of life for patients. To date, a standard treatment algorithm for the management of colorectal strictures of non-malignant origin has not been described. Therefore, it is necessary to carry out an individual analysis of each patient, and based on this, define whether management with a self-expanding metallic stent is the best treatment option.

## Compliance with ethical standards

**Informed consent:** The present study was considered without risk because it is a retrospective study. All procedures complied with the ethical standards of the committee responsible for human experimentation (national and institutional) and the Declaration of Helsinki of 1964 and later versions.

**Conflict of interest:** none declared by the authors.

**Funding:** The financing of the study was done with the authors' own resources, with support from the Sustainability Project of the Vice-Dean for Research of the University of Antioquia, Medellín, Colombia.

## Author's contributions

- Conception and design of the study: Rodrigo Castaño-Llano, Juan Darío Puerta-Díaz, Oscar Álvarez-Barrera.
- Acquisition of data: Rodrigo Castaño-Llano, Natalia Guzmán-Arango, Pablo Posada-Moreno, Romario Chanci-Drago, Juan Darío Puerta-Díaz, Isabella Cadavid-Agudelo, Juan Esteban Puerta Botero, Oscar Álvarez-Barrera.
- Data analysis and interpretation: Rodrigo Castaño-Llano, Natalia Guzmán-Arango, Pablo Posada-Moreno, Romario Chanci-Drago.
- Drafting the manuscript: Rodrigo Castaño-Llano, Natalia Guzmán-Arango, Pablo Posada-Moreno, Romario Chanci-Drago.
- Critical review: Rodrigo Castaño-Llano, Natalia Guzmán-Arango, Pablo Posada-Moreno, Romario Chanci-Drago.

## References

1. Cain BT, Huang LC. Benign colonic strictures. *Dis Colon Rectum*. 2021;64:1041-4. <https://doi.org/10.1097/DCR.0000000000002179>

2. Costa-Martins B, Fernandez-Oliveira J, Sakai P. Endoscopic management of benign colorectal strictures. En: Testoni PA, Inoue H, Wallace MB, editors. *Gastrointestinal and Pancreatico-Biliary Diseases: Advanced Diagnostic and Therapeutic Endoscopy*. Cham: Springer Nature Switzerland AG; 2022. p. 971-85. [https://doi.org/10.1007/978-3-030-56993-8\\_59](https://doi.org/10.1007/978-3-030-56993-8_59)
3. Adler DG. Colonic strictures: dilation and stents. *Gastrointest Endosc Clin N Am*. 2015;25:359-71. <https://doi.org/10.1016/j.giec.2014.11.001>
4. Di Nardo G, Oliva S, Passariello M, Pallotta N, Civitelli F, Frediani S, et al. Intralesional steroid injection after endoscopic balloon dilation in pediatric Crohn's disease with stricture: a prospective, randomized, double-blind, controlled trial. *Gastrointest Endosc*. 2010;72:1201-8. <https://doi.org/10.1016/j.gie.2010.08.003>
5. Truong S, Willis S, Schumpelick V. Endoscopic therapy of benign anastomotic strictures of the colorectum by electroincision and balloon dilatation. *Endoscopy*. 1997;29:845-9. <https://doi.org/10.1055/s-2007-1004319>
6. Lamazza A, Fiori E, Sterpetti AV, Schillaci A, Scoglio D, Lezoche E. Self-expandable metal stents in the treatment of benign anastomotic stricture after rectal resection for cancer. *Colorectal Dis*. 2014;16:O150-3. <https://doi.org/10.1111/codi.12488>
7. Suzuki N, Saunders BP, Thomas-Gibson S, Akle C, Marshall M, Halligan S. Colorectal stenting for malignant and benign disease: outcomes in colorectal stenting. *Dis Colon Rectum*. 2004;47:1201-7. <https://doi.org/10.1007/s10350-004-0556-5>
8. Martínez-Alcalá F, Martínez-Alcalá García FR, Sánchez-Yague A, Martínez-Alcalá García A, Ciria-Avila JA, Pérez-Pozo JM. Treatment of a benign, anastomotic refractory rectal stricture with an AXIOS stent. *Endoscopy*. 2015;47(Suppl 1 UCTN):E413-4. <https://doi.org/10.1055/s-0034-1392676>
9. Manterola C, Urrutia S. Use of self-expandable prosthesis for the treatment of colon and rectal benign stenosis. Systematic review. *Int J Med Surg Sci*. 2018;1:45-50. <https://doi.org/10.32457/ijmss.2014.007>
10. Lamazza A, Fiori E, Schillaci A, Sterpetti AV, Lezoche E. Treatment of anastomotic stenosis and leakage after colorectal resection for cancer with self-expandable metal stents. *Am J Surg*. 2014;208:465-9. <https://doi.org/10.1016/j.amjsurg.2013.09.032>
11. Fiori E, Lamazza A, Sterpetti AV, Crocetti D, De Felice F, Di Muzio M, et al. Quality of life for patients with incurable stage IV colorectal cancer: Randomized controlled trial comparing resection versus endoscopic stenting. *In Vivo*. 2019;33:2065-70. <https://doi.org/10.21873/invivo.11705>
12. Levine RA, Wasvary H, Kadro O. Endoprosthetic management of refractory ileocolonic anastomotic strictures after resection for Crohn's disease: report of nine-year follow-up and review of the literature. *Inflamm Bowel Dis*. 2012;18:506-12. <https://doi.org/10.1002/ibd.21739>
13. Hong JT, Kim TJ, Hong SN, Kim YH, Chang DK, Kim ER. Uncovered self-expandable metal stents for the treatment of refractory benign colorectal anastomotic stricture. *Sci Rep*. 2020;10:19841. <https://doi.org/10.1038/s41598-020-76779-8>
14. Caruso A, Conigliaro R, Manta R, Manno M, Bertani H, Barbera C, et al. Fully covered self-expanding metal stents for refractory anastomotic colorectal strictures. *Surg Endosc*. 2015;29:1175-8. <https://doi.org/10.1007/s00464-014-3785-2>