Rev Colomb Cir. 2025;40:169-75
https://doi.org/10.30944/20117582.2451

CASE PRESENTATION

# Wilkie syndrome – Does a dilated stomach change anything?

## Síndrome de Wilkie – ¿El estómago dilatado cambia algo?

Nafer Anaya, MD[1], Fredy Ávila, MD[2]

1 Department of Surgery, Clínica La Colina. Bogotá, D.C., Colombia.
2 Department of Gastroenterology, Clínica La Colina. Bogotá, D.C., Colombia.

## Abstract

**Introduction.** Mesenteric clamp syndrome corresponds to an extrinsic compression of the third portion of the duodenum, secondary to a decrease in the aorto-mesenteric angle, which generally occurs after a period of acute protein-calorie malnutrition.

**Clinical case.** A case of 20-year-old male is presented, who after a change to a vegan diet and an excessive exercise regimen, presents with epigastric pain associated with abdominal distention.

**Results.** Computed tomography was performed in which the decrease in the aorto-mesenteric angle and the decrease in the distance between these two structures were documented.

**Conclusions.** Due to the low frequency of this disease, there is no consensus about what the best treatment option is. It is also known if there is any role for gastrectomy when the stomach is dilated. There is not enough evidence to ensure that the dilated stomach and duodenum return to their previous size. Likewise, there is no certainty about the implications that air in the portal vein has for these cases. The case brought into consideration allows us to affirm that the best initial is nutritional support. In these cases, the stomach returns to its initial size once the extrinsic compression is corrected, just as the air disappears in the portal vein.

**Keywords:** superior mesenteric artery; superior mesenteric artery syndrome; gastric dilation; duodenal obstruction; portal vein; abdominal pain.

Received: 08/29/2023 - Accepted: 02/16/2024 - Published online: 08/1/2024.
Corresponding author: Nafer Anaya, Calle 167 # 72-7, Bogotá, D.C., Colombia. Tel.: +571 4897000. E-mail: naferjr@gmail.com
Cite as: Anaya N, Ávila F. Síndrome de Wilkie – ¿El estómago dilatado cambia algo? Rev Colomb Cir. 2025;40:169-75. https://doi.org/10.30944/20117582.2451

This is an open Access under a Creative Commons License - BY-NC-ND https://creativecommons.org/licenses/by-ncnd/4.0/deed.es

## Resumen

**Introducción.** El síndrome de pinza mesentérica corresponde a una compresión extrínseca de la tercera porción del duodeno, secundario a la disminución del ángulo aorto-mesentérico, que generalmente sucede después de un período de desnutrición proteico-calórica aguda.

**Caso clínico.** Se presenta el caso de un hombre de 20 años, quien posterior a un cambio a dieta vegana y un régimen de ejercicio excesivo, presenta dolor en epigastrio asociado a distensión abdominal.

**Resultados.** Se realizó una tomografía computarizada en la que se documentaron la disminución del ángulo aorto-mesentérico y la disminución en la distancia entre estas dos estructuras.

**Conclusiones.** Dada la baja frecuencia de casos de esta patología, no existe consenso acerca de cuál es la mejor opción de tratamiento. Tampoco se sabe si existe algún papel para la gastrectomía cuando el estómago está dilatado. No hay suficiente evidencia que permita asegurar que el estómago y el duodeno dilatados retornan a su tamaño previo. Así mismo, hay incertidumbre acerca de las implicaciones que tiene el aire en la vena porta para estos casos. El caso traído a consideración permite afirmar que la mejor terapia inicial es el soporte nutricional; en estos casos el estómago retorna a su tamaño inicial una vez corregida la compresión extrínseca, así como desaparece el aire en la vena porta.

**Palabras clave:** arteria mesentérica superior; síndrome de la arteria mesentérica superior; dilatación gástrica; obstrucción duodenal; vena porta; dolor abdominal.

## Introduction

Aorto-mesenteric clamp syndrome, also known as Wilkie syndrome, chronic duodenal ileus or Cast syndrome [1], is a pathological entity in which there is compression of the third portion of the duodenum, secondary to the decrease in the angle formed between the aorta and the superior mesenteric artery (SMA). The first to describe it was Von Rokitansky, who mentioned that it was a syndrome in which intermittent vomiting occurs, secondary to compression of the duodenum as it passes between the aorta and the SMA. Subsequently, Wilkie published a series of 57 cases of chronic duodenal ileus treated with surgery [2].

This syndrome is more common in women and occurs predominantly in patients with anorexia nervosa, although it has also been described in patients who, due to a medical condition, present marked weight loss, such as neoplasms, spinal surgery or bariatric surgery. It has been theorized that this syndrome occurs due to accelerated weight loss, which leads to a state of catabolism, with consumption of visceral fat, including the fat surrounding the mesentery and great vessels, such as the aorta and SMA.

Symptoms include postprandial vomiting, epigastric pain, and gastric fullness feeling, which further decreases intake and therefore leads to acute protein-calorie malnutrition. Usually, these patients arrive at the Emergency Department severely dehydrated, with hydroelectrolyte alterations and, on some occasions, with renal failure secondary to hypovolemia. However, once these situations are corrected, they are discharged, which is why they become repeated patients.

There must be a high degree of clinical suspicion on the surgeon evaluating the case. Once there is diagnostic doubt, it can be confirmed with different types of images, such as X-ray of the digestive tract, in which dilation of the stomach and duodenum is seen, with an abrupt obstruction at the level of its third portion; gastric emptying studies show delayed gastric emptying, as well as food retention [2]. Nowadays, computed tomography (CT) has a leading role in diagnosis, since it not only allows visualization of the dilation of the stomach and duodenum proximal to the third portion due to the compression between the aorta and the SMA, but it also allows measuring the aorto-mesenteric angle in the sagittal sections

(normal between 25-60 degrees) and the distance between the aorta and the SMA in the axial section (normal between 10-28 mm) [1].

Endoscopy of the upper digestive tract usually shows gastric stasis, food retention, and findings compatible with gastritis or erosive duodenitis; obstruction, sometimes pulsatile, can also be visualized at the level of the duodenum wall [2]. It is important to perform gastric lavage with 0.9% normal saline solution through a nasogastric tube before performing this exam, in order to empty the stomach and obtain better visualization. Once the examination is completed, a nasoenteral tube with a tungsten tip must be positioned, through which enteral nutrition can then be started.

Within the differential diagnosis there are two related entities, one is the medial arcuate ligament syndrome [3], in which there may be extrinsic compression of the celiac trunk, secondary to a fibrous tissue that forms on the diaphragm and generates compression when passing the aortic hiatus; this generates pain in the epigastrium. The second entity is the nutcracker syndrome [4], which corresponds to an extrinsic compression of the left renal vein, as it passes through the aorto-mesenteric angle; this condition produces pain that worsens with movement, and hematuria.

The treatment of mesenteric clamp syndrome has 3 stages. A first stage in which intravenous fluids must be provided to correct dehydration and kidney failure. Sodium, potassium, chlorine and phosphorus must be requested in the bloodwork, in order to correct them; it must be kept in mind that, before instituting any type of nutritional therapy, phosphorus must be corrected, seeking to avoid refeeding syndrome and its complications. A nasogastric tube should be placed to evacuate the stomach and lavage with sterile 0.9% normal saline solution should be performed until drainage is clear.

In the second stage, the diagnosis will be expanded by performing a CT and an endoscopy of the upper digestive tract, which also serves to advance a nasoenteral tube; an intervention should be initiated by the nutritional support group, preferring the enteral over the parenteral route as much as possible. The use of long acting prokinetics is recommended. The third stage of treatment is reserved for those cases in which there is no clinical improvement, due to persistence of pain and vomiting, as well as in cases in which duodenal dilation becomes persistent and progressive. For these patients, surgical intervention can be considered to relieve extrinsic compression on the duodenum. Interdisciplinary management is important to define whether there is benefit from surgical intervention or what is the best time for surgery, given that we are dealing with patients with protein-calorie malnutrition and with a high risk of failure in the anastomosis and fistula, complications that in a malnourished patient can lead to death.

Surgical techniques include the Strong procedure, vascular reimplantation and duodenal-jejunostomy [5]. The Strong procedure involves the release of the angle of Treitz, as well as the release of the duodenum, to displace it from the aorto-mesenteric angle. Vascular reimplantation of the SMA into the infra-renal aorta is clearly described for the management of chronic occlusive ischemia and may have a role in mesenteric clamp syndrome. However, the most accepted intervention for these cases is duodenojejunostomy, either openly, as performed for the first time by Stavely in 1908, or laparoscopically, as performed by Gersin & Heniford in 1998 [6]. This intervention is an important tool in patients with very dilated stomachs, in addition to the benefits of minimally invasive surgery; however, it can have complications such as bile reflux, anastomotic ulcer and fistula, among others. In our environment there are successful cases managed laparoscopically, as described in 2018 by Vásquez et al. [7], although it is not yet clearly determined which is the best intervention.

## Clinical case

The case of a 20-year-old man is presented, who four years earlier began a vegan diet and in the last 4 months added a strict exercise regimen. He had had 5 previous visits to the Emergency Department (ED) due to pain in the epigastrium,

associated with multiple episodes of vomiting, which improved with hydration, and was discharged. In this last episode, he reported pain in the epigastrium, gastric fullness feeling and vomiting in large quantities, associated with oliguria, jaundice and generalized weakness. The laboratories reported leukocytes 10,870 x 109/L, neutrophils 76%, hemoglobin 17 g/dL, platelets 287,000 x 109/L, INR 1.13, prothrombin time (PT) 11.8 seconds, partial thromboplastin time (PTT) 22.8 seconds, creatinine 1.26 mg/dL, potassium 4.22 mEq/L, sodium 137 mEq/L, phosphorus 2.68 mg/dL, albumin 5.4 mg/dL, amylase 59 U/L, total bilirubin 4.5 mg/dL and indirect bilirubin 4.0 mg/dL, glutamic-oxaloacetic transaminase (GOT) or aspartate aminotransferase (AST) 17 U/L, glutamic pyruvic transaminase (GPT) or alanine transaminase (ALT) 16 U/L and urinalysis without hematuria.

Upon admission to the ED, hydration with intravenous fluids and antiemetic management were initiated. He was evaluated by General Surgery and it was decided to perform a CT scan, which documented a marked dilation of the stomach, which almost contacted the dome of the bladder, with pneumatosis of the wall, predominantly at the lower edge and greater curvature of the stomach, associated with air in the portal vein, which could be differentiated from pneumobilia, given that it compromised the 2 cm closest to the Gleason capsule. In detailed review of the image, an aorto-mesenteric angle of 16 degrees in the sagittal section and a distance between the aorta and SMA of 2.5 mm in the axial section was documented (Figure 1). The diagnosis of mesenteric clamp syndrome was confirmed.

An upper digestive tract endoscopy was performed, which revealed erosive gastritis, and a tungsten-tipped nasoenteral tube was advanced beyond the site of extrinsic compression. With a weight of 38.3 kg at that time, enteral nutrition was started through the tube, but in the first week of treatment dysfunction due to occlusion occurred three times, probably related to the clamp, which is why parenteral nutrition was started. In addition, he received follow-up from Psychiatry, who considered that he had major depression and began management with Fluoxetine in oral suspension. On the part of Gastroenterology, Domperidone was added to the management.

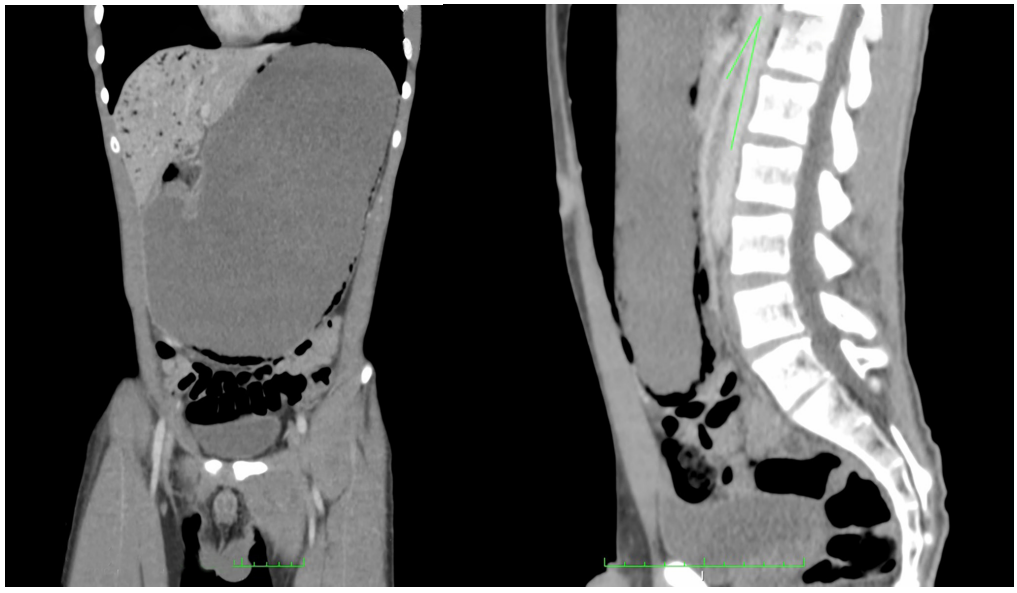

**Figure 1.** Initial abdominal CT scan, before treatment with nutritional support, showing a very dilated stomach, air in the portal vein, and an aorto-mesenteric angle of 16 degrees.

Source: image obtained by the authors with authorization from the patient.

The patient had obvious clinical and emotional improvement, without vomiting or abdominal pain, and the jaundice disappeared. A month later it was decided to take a control CT, in which the disappearance of air in the portal and return of the stomach to its normal size was observed, with disappearance of the pneumatosis in the wall; there was an increase in the aorto-mesenteric angle to 28.9 degrees in the sagittal section, with contrast medium passing into the distal ileum and an increase in the aorto-mesenteric distance to 5.2 mm in the axial section (Figure 2).

Given the clinical and radiological improvement, it was decided to restart the oral route progressively, with good tolerance, and weaning from parenteral nutrition until it was withdrawal and subsequent discharge. In the outpatient follow-up, an asymptomatic patient was found, with a weight increase to 43.6 kg, two months after starting treatment.

## Discussion

Although it is true that there is consensus on the diagnosis of mesenteric clamp syndrome, given by the standardization in the measurement of the aorto-mesenteric angle and the distance between the aorta and the SMA, a consensus has not been reached on the treatment, probably given the low prevalence of this pathology. In the treatment process of these patients, controversies arise, which we want to comment on considering what we learned with this case.

### *What to do with cases where pneumatosis occurs in the stomach wall and air in the portal vein?*

Generally, pneumatosis in the wall of a viscus is caused by some ischemic phenomenon on its wall. In this case, it does not have the same implications as pneumatosis in the small intestine, where it is generally an ominous sign, while in the stomach it can be secondary to ulcers and obstructions of the stomach outflow tract.

The presence of air in the portal vein, also described as 'aeroportia'[8], originates from intraluminal air or is produced by bacteria, which, given the increase in intraluminal pressure due to an obstructive or ischemic phenomenon, is pushed

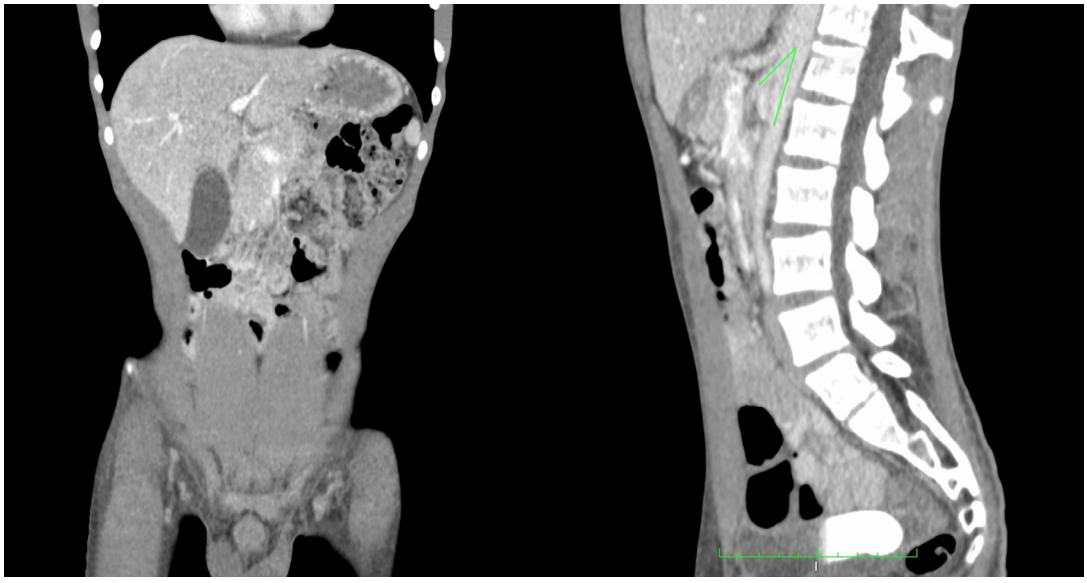

**Figure 2.** CT of the abdomen after one month of treatment with nutritional support, which shows that the stomach has returned to its usual size, there is no air in the portal vein and the aorto-mesenteric angle measures 28.9 degrees.

Source: image obtained by the authors with authorization from the patient.

through the gastric mucosa towards the venous or lymphatic vessels, and from there, to the hepatic portal system. There is no pathogen associated with this condition. It should not be confused with pneumobilia, which is associated with previous interventions in the bile duct, mainly endoscopic retrograde cholangiopancreatography (ERCP); the tomography shows air, predominantly hilar, without compromising the last 2 cm of the liver before contacting the Gleason capsule. What we learned from the case is that it has no implication in the severity of the condition and does not require any antibiotic management. There is no published evidence that supports the conduct of giving antibiotic management when there is pneumatosis intestinalis or the presence of air in the portal vein.

### *Does a dilated stomach change anything?*

The stomach of these patients suffers chronic dilation. Under this principle, is it expected to return to its normal size?

There is no clarity about whether gastric dilation in these patients occurs chronically or acutely, causing pain, which becomes the reason for consultation. However, we do not consider that it behaves like other causes of gastric atony and dilation in which it remains dilated despite management. In the case mentioned, the stomach returned to its previous size, as documented by the control CT scan one month after treatment. An additional consideration is that changes in the angles were evident just one month apart, therefore, this could be an objective measure of the effectiveness of the treatment to be used.

### *Is nutritional treatment or any surgical intervention superior?*

There is no scientific evidence of Level A1 and it is unlikely that it will be achieved in the coming years given the low prevalence of the pathology. Despite this, all publications, which are mostly reports or case series, put conservative medical management first, with nutritional support, and leave surgery for those cases in which there is no improvement with nutritional treatment, there is persistence of pain and vomiting or progression of duodenal dilation.

### *When faced with a dilated and atonic stomach, is there a role for resective surgery in the treatment?*

Given the situation of a patient with this clinical entity, with a stomach that does not return to its normal size, and if it is decided to undergo surgery, the possibility of performing a subtotal gastrectomy with a gastro-jejunostomy or a Roux-en-Y reconstruction always comes into consideration. However, there is no evidence to support this behavior. Most documented patients have been treated with duodenal-jejunostomy, which, to date, continues to be the gold standard in the treatment of patients with surgical indications.

## Conclusions

The case brought into consideration allows us to affirm that the best initial therapy is nutritional support, whether enteral or parenteral. In these cases, the stomach returns to its initial size once the extrinsic compression is corrected, as well as the presence of air in the portal vein returns. Antibiotic treatment is not necessary in the presence of 'aeroportia'. There are a few cases that require surgical intervention, which, if indicated, should be a duodeno-jejunostomy. The surgical approach can be open or laparoscopic; however, this decision must be made based on the availability of resources and the experience of the surgeon.

## Compliance with ethical standards

**Informed consent:** This publication was done with the informed consent of the patient. It was approved by the Institutional Ethics Committee and in accordance with Resolution 008430 of 1993 of the Ministry of Health of Colombia, this is a risk-free investigation.

**Conflicts of interest:** The authors declared that they have no conflicts of interest.

**Use of Artificial Intelligence:** The authors declared that no technologies assisted by artificial intelligence were used in its preparation.

**Funding:** No external source.

**Author's contribution:**

- Conception and design of the study: Nafer Anaya, Freddy Ávila.
- Acquisition of data: Nafer Anaya, Freddy Ávila.
- Data analysis and interpretation: Nafer Anaya, Freddy Ávila.
- Drafting the manuscript: Nafer Anaya, Freddy Ávila.
- Critical review and final approval: Nafer Anaya, Freddy Ávila.

## References


1 Madhu B, Govardhan B, Krishna B. Cast syndrome. Oxf Med Case Reports. 2019;4:omz025. https://doi.org/10.1093/omcr/omz025

2 Cardoso-Barchi L, Alves AM, Jacob CE, Caldas-Bresciani CJ, Yagi OK, Nogueira TG, et al. Favorable minimal invasive surgery in the treatment of superior mesenteric artery syndrome: Case report. Int J Surg Case Rep. 2016;29:223-6. https://doi.org/10.1016/j.ijscr.2016.09.016

3 Fujiwara Y, Higashida M, Kubota H, Watanabe Y, Ueno M, Uraoka M, et al. Laparoscopic treatment of median arcuate ligament syndrome in a 16-year-old male. Int J Surg Case Rep. 2018;52:79-83. https://doi.org/10.1016/j.ijscr.2018.10.006

4 Kurklinsky AK, Rooke TW. Nutcracker phenomenon and nutcracker syndrome. Mayo Clin Proc. 2010;85(6):552–9. http://dx.doi.org/10.4065/mcp.2009.0586

5 Beitia E. Duodenoyeyunostomía laparoscópica como tratamiento del síndrome de la arteria mesentérica superior. Cir Esp. 2014;92:129–31. https://doi.org/10.1016/j.ciresp.2013.06.020

6 Gersin KS, Heniford BT. Laparoscopic duodenojejunostomy for treatment of superior mesenteric artery syndrome. JSLS. 1998;2(3):281–4.

7 Vásquez JN, Durán MA, Vásquez C. Tratamiento mínimamente invasivo del síndrome de Wilkie. Rev Colomb Cir. 2018;33:299-306. https://doi.org/10.30944/20117582.75

8 Moldovanu CG, Caraiani C, Furnea B, Graur F. A rare case of aeroportia due to acute gastric dilatation - when the radiologist goes beyond the images. J Gastrointestin Liver Dis. 2020;29(1):3. http://dx.doi.org/10.15403/jgld-865.