Rev Colomb Cir. 2025;40:1181-7
https://doi.org/10.30944/20117582.2773

CASE PRESENTATION

Atypical retroperitoneal lipoblastoma

Lipoblastoma atípico retroperitoneal

Estephanie Arroyo-Burgos, MD[1,2], Daniela Díaz-Córdova, MD[1,2], Noe Rodríguez-Moreno, MD[1], César Sánchez-Marín, MD[1,3]

1 Hospital Regional Lambayeque, Lambayeque, Perú.
2 Universidad Peruana Antenor Orrego, Trujillo, Perú.
3 Universidad César Vallejo, Piura, Perú.

Abstract

Introduction. Lipoblastoma is a benign mesenchymal tumor that occurs in children under 3 years of age, typically in the lower extremities, and with limited symptoms. The objective is to present a clinical case of atypical retroperitoneal lipoblastoma and review the literature on this condition.

Clinical case. A 3-year-old male child presented with diffuse abdominal pain and hyperoxia. The mother reported a progressively growing, painless abdominal mass in the pelvic region. Imaging studies confirmed a retroperitoneal tumor consistent with lipoblastoma.

Results. Successful surgical resection was performed, and histopathological examination confirmed the diagnosis. The patient experienced no recurrences and had a favorable outcome after 2 years of follow-up.

Conclusions. This case underscores the importance of considering lipoblastoma in the differential diagnosis of abdominal masses in children and the need for complementary studies for a definitive diagnosis and appropriate management. Lipoblastoma is a rare condition with challenging differential diagnosis, highlighting the importance of histopathological and cytogenetic studies for accurate diagnosis.

Keywords: lipoblastoma; retroperitoneal neoplasms; pediatrics; differential diagnosis; computed tomography.

Resumen

Introducción. El lipoblastoma es un tumor mesenquimatoso benigno que se presenta en niños menores de 3 años, típicamente en las extremidades inferiores y con síntomas limitados. El objetivo de este artículo fue presentar un caso clínico de lipoblastoma retroperitoneal atípico y revisar la literatura sobre esta condición.

Caso clínico. Niño de 3 años de edad con cuadro de dolor abdominal difuso e hiperoxia. La madre refirió una masa abdominal indolora y de crecimiento progresivo en la región pélvica. Los estudios de imagen confirmaron un tumor retroperitoneal compatible con lipoblastoma.

Received: 09/24/2024 - Accepted: 11/15/2024 - Published online: 01/07/2025
Corresponding author: César Sánchez-Marín, Av. Salaberry 283, José Olaya, Chiclayo (14001), Perú. Tel.: +51 987593528.
E-mail: csmarin90@gmail.com
Cite as: Arroyo-Burgos E, Díaz-Córdova D, Rodríguez-Moreno N, Sánchez-Marín C. Atypical retroperitoneal lipoblastoma. Rev Colomb Cir. 2025;1181-7. https://doi.org/10.30944/20117582.2773

This is an open Access under a Creative Commons License - BY-NC-ND https://creativecommons.org/licenses/by-ncnd/4.0/deed.es

Resultados. Se hizo una resección quirúrgica exitosa y el examen histopatológico confirmó el diagnóstico. El paciente no experimentó recurrencias y tuvo una evolución favorable después de dos años de seguimiento.

Conclusiones. Este caso subraya la importancia de considerar el lipoblastoma en el diagnóstico diferencial de las masas abdominales en niños, así como la necesidad de estudios complementarios para un diagnóstico definitivo y un manejo adecuado. El lipoblastoma es una afección rara con un diagnóstico diferencial desafiante, por lo que se destaca la importancia de los estudios histopatológicos y citogenéticos para un diagnóstico preciso.

Palabras clave: lipoblastoma; neoplasias retroperitoneales; pediatría; diagnóstico diferencial; tomografía computarizada.

Introduction

This pathology was first described in 1926 by Jaffe, who reported recurrent lipomatous tumors in the groin consisting of embryonic fat cells. Conversely, van Meurs in 1947, after a series of surgical interventions in a patient, demonstrated the capacity for differentiation into common or mature lipomas, confirming the embryonic origin of this tumor. In 1958, Vellios coined the term "lipoblastomatosis" in his report and delineated the differences from hibernomas, rare tumors of brown fat. Subsequently, in 1973, Chung and Enzinger, after a series of 35 cases, the most extensive in scientific literature at the time, recommended the use of the term "benign lipoblastoma" for well-localized, subcutaneous, circumscribed, and encapsulated cases, reserving the term "lipoblastomatosis" for deep, multilobulated, non-encapsulated, diffuse lesions with a tendency for metastasis [1-3].

In 1993, the cytogenetic characteristics generated by the alteration of chromosome 8q12 were specified, aiding in differentiation from other soft tissue tumors, such as liposarcoma. In 1997, Collins and Chatten detailed the histopathology of these tumors. Despite these advancements, O'Donnell in 2000 referred to the term "blastoma" as generating confusion due to its non-malignant behavior, thus proposing the term "infantile lipoma" to describe the histopathology of the tumor, although it is rarely used today [3,4].

Various cases have been described in Latin America, with the first report of this pathology made in Mexico. Zárate in 1991 described a mediastinal tumor in a 14-year-old child. In Perú, Garaycochea in 2007 described this clinical picture for the first time, and currently it remains the only report published in the literature, reporting a giant mesenteric tumor in a 1-year-old girl, with subsequent surgical resection and favorable outcome [5-7].

The objective of this article is to report an atypical case of double circumscribed retroperitoneal lipoblastoma, a very uncommon presentation in an infant, by presenting relevant literature to aid in the differential diagnosis.

Clinical case

A 3-year-old male patient, with no personal or family history of illness, presented to the emergency room with a clinical picture of diffuse abdominal pain of a few days' duration and hyporexia. The mother reported an abdominal mass in the pelvic region, predominantly on the right, mobile, progressively growing, painless and without modifications in bowel movements or diuresis. The parents brought him to his local health center, where he was referred to a hospital.

On physical examination, the patient only palpated a 10 x 6cm mass in the right pelvic region, with a soft consistency, mobility, dullness on percussion and mild pain on deep palpation that extended beyond the midline.

An abdominopelvic computed tomography (CT) with contrast was performed, which described an extensive abdominopelvic mass with lobulated edges, hypodense content with some areas and isodense septa, of heterogeneous appearance, that does not enhance with contrast, measuring 119 x 93 x 75 mm, predominantly within the pelvic cavity and

the lower right quadrant. The extensive and heterogeneous abdominopelvic mass caused mass effect in the adjacent structures, and liposarcoma was considered in the differential diagnosis (Figure 1).

Following surgical extraction, the macroscopic examination revealed two tumors weighing a total of 480 grams. The larger fragment measured 9 x 10 x 7.5 cm, and the smaller one measured 8.7 x 7 x 4.5 cm. Both tumors exhibited smooth multinodular surfaces with congestive areas and adipose-like appearances, with a 0.2 cm capsule and increased consistency (Figure 2).

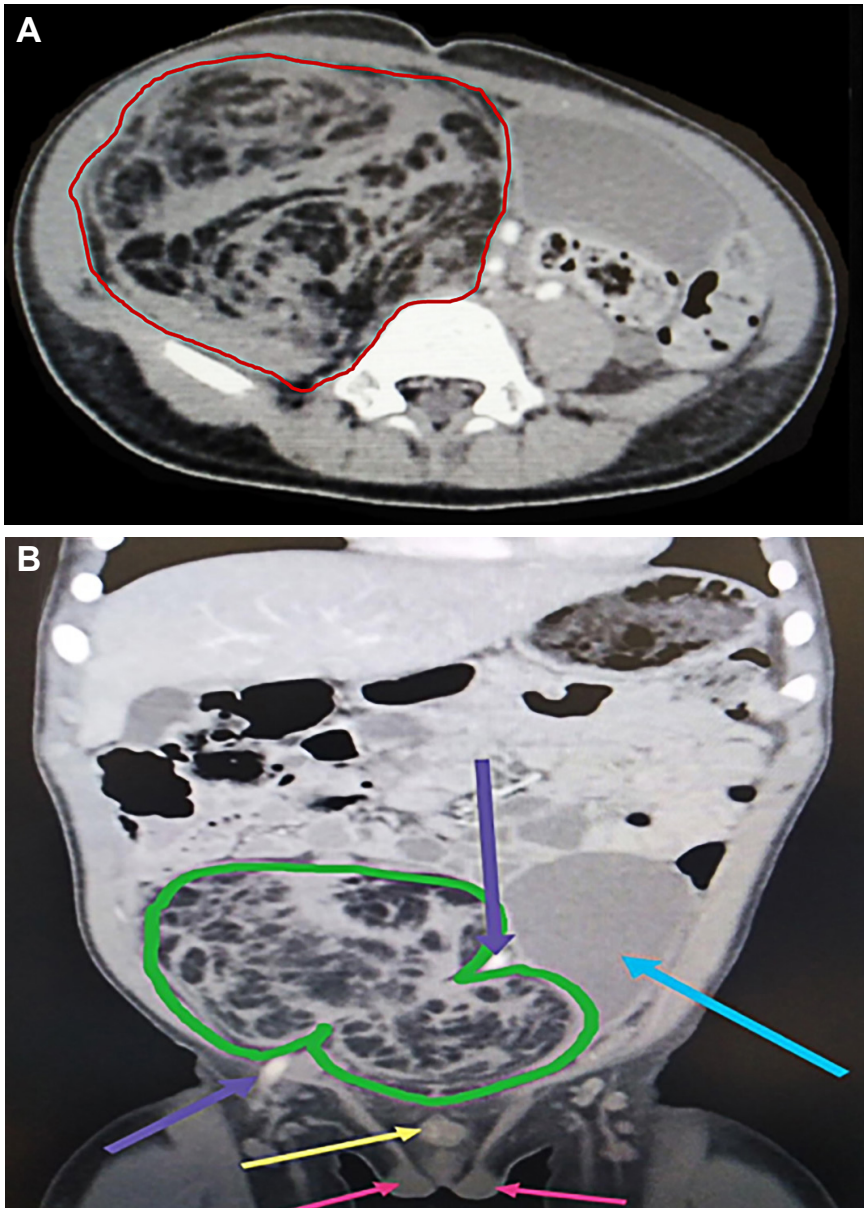

Figure 1. Contrast-enhanced abdominopelvic computed tomography (CT).

A. Transverse section of the lower abdomen. Red line: A large mass of solid and fatty tissue is evident, compressing and displacing adjacent organs, resulting in an asymmetrical abdominal wall. **B.** Coronal section at the level of the lower abdomen. Green line: Retroperitoneal tumor reaching the pelvic floor (the levator ani muscles). Purple arrows: Point to the iliac vessels passing at the level of the neck of the tumor. Blue arrow: Points to the compressed bladder displaced to the left. Yellow arrow: Infantile penis. Red arrows: Infantile testicles.

Source: Photograph taken by the authors.

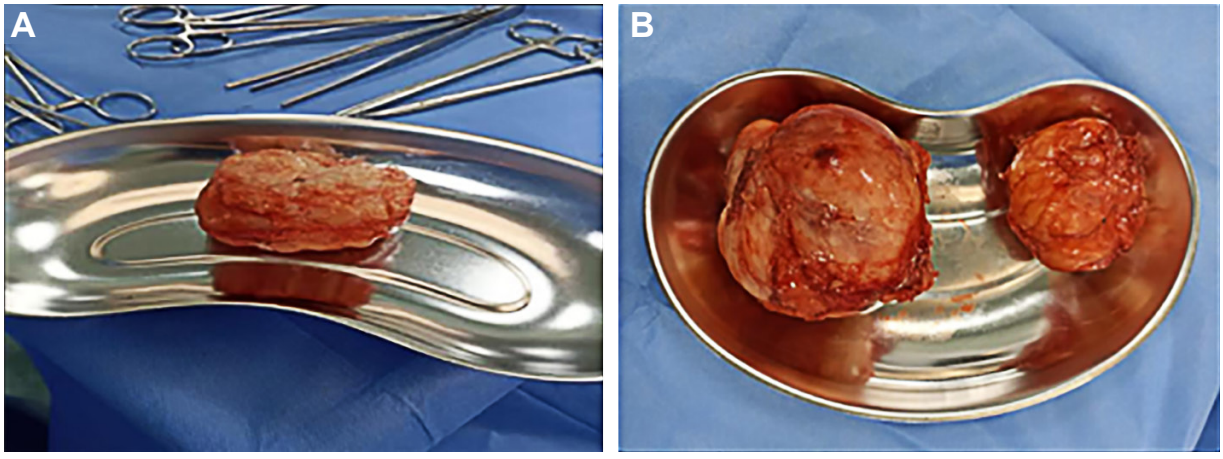

Figure 2. Post-surgical macroscopic specimen. A. Image of the initial extraction. B. Image of the subsequent extraction of both tumors.

Source: Photograph taken by the authors.

Microscopic examination showed histopathological features consistent with lipoblastoma with myxoid areas, characterized by numerous adipocytes, a rich capillary vascular network, and fibrous septa. Cytogenetic studies were not necessary (Figure 3).

The patient was discharged without complications and with a favorable evolution. The patient was subsequently followed up for months after surgery, with no evidence of recurrence.

Discussion

Lipoblastoma is a benign fatty tumor that occurs exclusively in childhood, representing 5-30% of adipose tumors in pediatric patients. There are two clinical forms of this pathology: circumscribed masses, localized predominantly in the subcutaneous tissue of the extremities, accounting for 70% (benign lipoblastoma), and the infiltrative and diffuse form located deeper, termed lipoblastomatosis, accounting for 30% of cases [4,5]. Most cases are detected in children under 3 years of age (80-90%). Seventy percent of lipoblastomas are found in the extremities, trunk, neck, and head. Retroperitoneal lipoblastomas are less common, with an incidence of up to 5% of cases [3,4].

The use of CT and Magnetic Resonance Imaging (MRI) is recommended to narrow the diagnostic possibilities by providing information on the position, depth, and anatomical relationships of the lesion, considering the tumor limits for resection. For this, vascular intensity on T1-weighted images serves to differentiate them from lipomas [6,8]. Additionally, on these same images, due to the fatty nature of the tissue, lipoblastomas typically exhibit intermediate signal intensity due to immature lipoblasts on T1 and hyperintense and heterogeneous signal on T2 [3,8].

For definitive diagnosis, histopathological and cytogenetic studies are required. Thus, obtaining a tissue sample through core needle biopsy is suggested before surgical resection, which remains the definitive treatment with few complications. Routine monitoring is not recommended due to the low probability of recurrence, but for these cases, MRI is the best method [8-10].

In our case report, despite having atypical characteristics of a benign tumor as a double encapsulated mass, there were no issues with recurrence or metastasis during follow-up. Fortunately, lipoblastoma has a good long-term prognosis, with no reported cases of metastasis, although recurrence rates vary between 14-25%, mainly attributed to incomplete excisions. In some cases, lipoblastomas can mature or spontaneously regress [8,10,11].

Histopathological diagnosis confirms its benign nature, characterized by the presence of

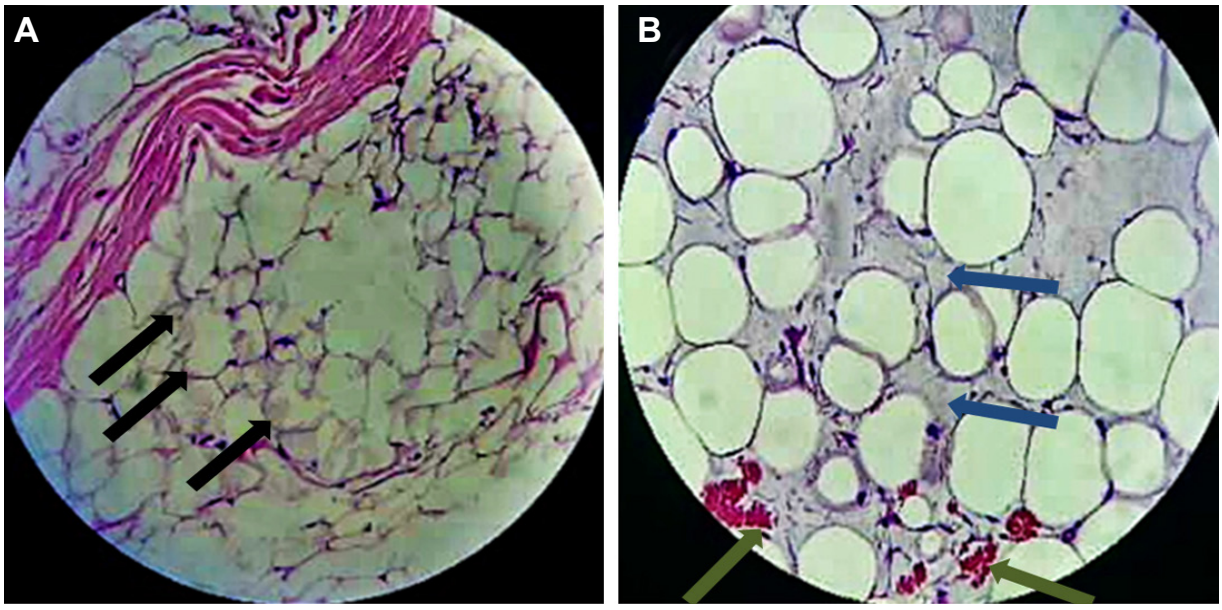

Figure 3. Microscopic examination. **A.** Histological section showing typical features of lipoblastoma (Hematoxylin and eosin stain, 40x). Black arrows: Displaying adipocytes at different stages of differentiation with the presence of myxoid mesenchymal matrix. **B.** Blue arrows: Thin septa. Green arrows: Vascular capillary structure, with partial infiltration of adjacent muscle.
Source: Photograph taken by the authors.

adipocytes at different stages of differentiation embedded in a myxoid stroma with connective tissue septa and no atypical cells [5,7]. Lipoblastoma consists mainly of mature fat cells, with fewer embryonic mesenchymal cells, lipoblasts, spindle cells, and mature adipocytes organized into lobules separated by fibrous septa forming a plexiform capillary network. Unlike simple lipomas, which lack lipoblasts and primitive mesenchymal cells and typically do not present lobulations, lipoblastomas are typically not found in the extremities and usually do not exhibit chromosomal abnormalities [12,13].

When histology is inconclusive, cytogenetics ultimately defines the diagnosis, considering that this pathology is associated with chromosomal abnormalities at 8q11-13. It has been observed that approximately 70-82% of lipoblastomas present abnormalities in the pleomorphic adenoma gene 1 oncogene (PLAG1) located on chromosome 8q12, and approximately 18% show polysomy on this chromosome [10,12]. The PLAG1 gene participates in cellular processes such as mitogenesis, proliferation, apoptosis and the positive regulation of insulin-like growth factor II. Overexpression of this gene leads to the replacement of the PLAG1 promoter by an associated promoter of fusion more active [10,13].

In the differential diagnosis of lipoblastoma, simple lipoma, myxoid liposarcoma, well-differentiated liposarcoma/atypical lipomatous tumor should be included, although rare in the typical age of lipoblastomas, and show molecular alterations such as t(12;16) (q13; p11) translocation leading to alterations in the fusion genes FUS and DDIT3 [11,12,14].

Retroperitoneal location is particularly rare, often presenting large tumors (less than 30 well-documented cases), posing a diagnostic and preoperative therapeutic challenge. The differential diagnosis in this location mainly includes malignant tumors such as sarcomas, nephroblastomas, neuroblastomas, and teratomas. While histopathology is the basis for its diagnosis,

molecular diagnostic approaches can be a useful adjunct in difficult cases, recommending routine cytogenetic analysis for all patients [8,14,15].

Conclusion

Lipoblastoma is a rare benign mesenchymal tumor with no metastatic potential, which occurs specifically in children under 3 years of age and usually in the lower extremities. Diagnosis is often incidental due to limited symptoms and depends on the site of origin. Definitive treatment is complete surgical resection, with good results and a low recurrence rate. Currently, the etiopathogenesis of benign adipose tissue tumors remains a subject of study, despite advances in cytogenetic analysis and imaging to identify specific chromosomal abnormalities in lipoblastomas and imaging characteristics. Lipoblastoma is considered a childhood tumor with a good prognosis, but its differential diagnosis remains a challenge with other malignant lesions, so close follow-up is necessary if the means for cytogenetic studies are available.

Compliance with ethical standards

Informed consent: Informed consent was requested from the mother and approval was obtained from the Institutional Research Ethics Committee of the Lambayeque Regional Hospital through authorization N° 004-2024.

Conflicts of interest: The authors declare no conflicts of interest.

Use of Artificial Intelligence: Artificial intelligence was not used in this article.

Funding: The authors received no financial support.

Author's contribution:

- Conception and design of the study: Estephanie Arroyo-Burgos, Daniela Díaz-Córdoba, Noé Rodríguez-Moreno.
- Acquisition of data: Estephanie Arroyo-Burgos, Daniela Díaz-Córdoba, Noé Rodríguez-Moreno.
- Data analysis and interpretation: Estephanie Arroyo-Burgos, Daniela Díaz-Córdoba, Noé Rodríguez-Moreno.
- Drafting the manuscript: Estephanie Arroyo-Burgos, Daniela Díaz-Córdoba, Noé Rodríguez-Moreno.

References

1 Hicks J, Dilley A, Patel D, Barrish J, Zhu SH, Brandt M. Lipoblastoma and lipoblastomatosis in infancy and childhood: histopathologic, ultrastructural, and cytogenetic features. Ultrastruct Pathol. 2001;25:321-33. http://doi.org/10.1080/019131201753136359

2 Serrano R, Vergara E, Lazala O. Lipoblastoma del hombro: reporte de caso. Revista Colombiana de Ortopedia y Traumatología. 2009;23:66-9.

3 Rajput S, Alsubaie SA, Singh K, Huang TC, Moran SL. Lipoblastoma of the extremities. J Plast Reconstr Aesthet Surg. 2022;75:3761-7. http://doi.org/10.1016/j.bjps.2022.06.077

4 Sakamoto S, Hashizume N, Fukahori S, Ishii S, Saikusa N, Yoshida M, et al. A large retroperitoneal lipoblastoma: A case report and literature review. Medicine (Baltimore). 2018;97:e12711. http://doi.org/10.1097/MD.0000000000012711

5 Gutiérrez J, Ruano J, De León B, Calderón C, Ásquez E, Duarte J, et al. Lipoblastoma en la infancia. Correlación clínico patológica en 16 casos. Acta Pediatr Méx. 2000;21:214-8.

6 Santamaría C, León D, Fabre E, Acosta D, Cabrera M, Acosta D. Lipoblastoma en la edad pediátrica. Presentación de dos casos en glúteo y tórax posterior. Canarias Pediátrica. 2022;46:35-9.

7 Garaycochea V. Lipoblastoma mesentérico en una niña: presentación de un caso y revisión de la literatura. Rev Peru Pediatr. 2007;60:182-7.

8 Spătaru R, Cîrstoveanu C, Iozsa D, Enculescu A, Tomescu LF, Șerban D. Lipoblastoma: Diagnosis and surgical considerations. Exp Ther Med. 2021;22:903. http://doi.org/10.3892/etm.2021.10335

9 Pollono D, Tomarchio S, Drut R, Zaritzky M, Otero L, Vazquez A, et al. Retroperitoneal and deep-seated lipoblastoma: diagnosis by CT scan and fine-needle aspiration biopsy. Diagn Cytopathol. 1999;20:295-7. http://doi.org/10.1002/(SICI)1097-0339(199905)20:5<295::AID-DC9>3.0.CO;2-K

10 Panda S, Bajpai M, Singh A. Recurrent lipoblastoma of upper extremity in a 9-year-old boy. BMJ Case Rep. 2014;2014:bcr2013201973. http://doi.org/10.1136/bcr-2013-201973

11 Gerhard-Hartmann E, Wiegering V, Benoit C, Meyer T, Rosenwald A, Maurus K, et al. A large retroperitoneal lipoblastoma as an incidental finding: a case report. BMC Pediatr. 2021;21:159. http://doi.org/10.1186/s12887-021-02628-w

12 Yoshida H, Miyachi M, Ouchi K, Kuwahara Y, Tsuchiya K, Iehara T, et al. Identification of COL3A1 and RAB2A as novel translocation partner genes of PLAG1 in lipoblastoma. Genes Chromosomes Cancer. 2014;53:606-11. http://doi.org/10.1002/gcc.22170

13 Nitta Y, Miyachi M, Tomida A, Sugimoto Y, Nakagawa N, Yoshida H, et al. Identification of a novel BOC-PLAG1 fusion gene in a case of lipoblastoma. Biochem Biophys Res Commun. 2019;512:49-52. http://doi.org/10.1016/j.bbrc.2019.02.154

14 Fallon S, Brandt M, Rodriguez J, Vasudevan S, Lopez M, Hicks M, et al. Cytogenetic analysis in the diagnosis and management of lipoblastomas: results from a single institution. J Surg Res. 2013;184:341-6. http://doi.org/10.1016/j.jss.2013.05.010

15 Rosière N, Falcioni A, Navacchia D, Giambini D. Giant retroperitoneal lipoblastoma. Case report. Arch Argent Pediatr. 2018;116:e139-42. http://doi.org/10.5546/aap.2018.e139