Rev Colomb Cir. 2025;40:1123-31
https://doi.org/10.30944/20117582.2872

ORIGINAL ARTICLE

Prevalence and risk factors of HPV associated neoplasms in patients with anal condyloma: A 10-year retrospective analysis at a secondary care hospital

Prevalencia y factores de riesgo de neoplasias asociadas al VPH en pacientes con condiloma anal: Análisis retrospectivo de 10 años en un hospital de atención secundaria

Javier O. Dagnesses-Fonseca, MD[1], Ana Montané-Peruzzo[2], Ainara Herrero-Mirón, MD[1], Naiara Ondarra-Fernández de Leceta, MD[1], Telma Meizoso-Latova, MD, PhD[3], Justyna Drewniak-Jakubowska, MD[1], David García-Teruel, MD, PhD[1], Adelino Patricio Pérez-Morera, MD, PhD[1], Javier Páramo-Zunzunegui, MD, PhD[1]

1 Department of Surgery, Hospital Universitario de Móstoles, Madrid, España.
2 Medical Student, Universidad Rey Juan Carlos, Hospital Universitario de Móstoles. Madrid, España.
3 Department of Pathology, Hospital Universitario de Móstoles, Madrid, España.

Abstract

Introduction. Infection with Human Papillomavirus (HPV) is the most common viral sexually transmitted infection. There are low-risk and high-risk oncogenic serotypes that can be associated with the development of condyloma acuminata, anal intraepithelial neoplasia (AIN), or anal carcinoma. This study aims to analyse the prevalence of histopathological findings of anal condyloma acuminata treated at a secondary care hospital in Spain.

Methods. A descriptive, analytical, and retrospective study was conducted on patients with anal condyloma acuminata operated on at a secondary care hospital between 2013 and 2023.

Results. A total of 124 patients were included: 92 (74.2%) men, 72 (58.1%) smokers, 32 (25.8%) HIV-positive, and 10 (8.1%) with other immunosuppression. AIN of any grade was present in 23.4% of patients. There was a significant association between HIV positivity and AIN (p=0.005), particularly high-grade or advanced HSIL (p=0.007). No increased risk of AIN was observed with other immunosuppressions (p=0.3), but more multiple condylomatous lesions (p=0.028) or vulvar lesions (p=0.047) were noted. AIN was more frequent with high-risk HPV (84.6%; p<0.005). In 54.8% of the samples, no serological study of HPV was performed.

Received: 04/14/2025 - Accepted: 07/13/2025 - Published online: 03/09/2025
Correspondencia: Javier Oscar Dagnesses-Fonseca, Calle de Asturias 33, Villaviciosa de Odón, Madrid, España. CP 28670.
Tel.: + 34 655 092 381. E-mail: jdagnessesf@gmail.com
Cite as: Dagnesses-Fonseca JO, Montané-Peruzzo A, Herrero-Mirón A, Ondarra-Fernández de Leceta N, Meizoso-Latova T, Drewniak-Jakubowska J, et al. Prevalence and risk factors of HPV associated neoplasms in patients with anal condyloma: A 10-year retrospective analysis at a secondary care hospital. Rev Colomb Cir. 2025;40:1123-31. https://doi.org/10.30944/20117582.2872

This is an open Access under a Creative Commons License - BY-NC-ND https://creativecommons.org/licenses/by-ncnd/4.0/deed.es

Conclusions. The development of AIN is associated with known risk factors, such as HIV infection and oncogenic HPV serotypes. Protocolising the study of viral serotypes in samples of condyloma acuminata could improve surveillance in patients with high-risk serotypes.

Keywords: human papillomavirus viruses; condylomata acuminata; squamous intraepithelial lesions; anus neoplasms; general surgery.

Resumen

Introducción. La infección por el Virus del Papiloma Humano (VPH) es la infección viral de transmisión sexual más común. Existen serotipos oncogénicos de bajo y alto riesgo que se asocian con condilomas acuminados, neoplasia intraepitelial anal (NIA) o carcinoma anal. El objetivo de este estudio fue analizar los hallazgos histopatológicos en pacientes con condilomas acuminados anales tratados en un hospital de atención secundaria en España.

Métodos. Se realizó un estudio descriptivo, analítico y retrospectivo en pacientes con condilomas acuminados anales operados en un hospital de atención secundaria entre 2013 y 2023.

Resultados. Se incluyeron un total de 124 pacientes: 92 (74,2 %) hombres, 72 (58,1 %) fumadores, 32 (25,8 %) VIH positivos y 10 (8,1 %) con otras formas de inmunosupresión. Se observó NIA de algún grado en el 23,4 % de los pacientes. Se encontró una asociación significativa entre la positividad para VIH y la presencia de NIA (p=0,005), especialmente de lesiones escamosas intraepiteliales de alto grado avanzadas (p=0,007). No se observó un mayor riesgo de NIA en pacientes con otras inmunosupresiones (p=0,3), pero se detectaron más lesiones condilomatosas múltiples (p=0,028) o lesiones vulvares (p=0,047). La NIA fue más frecuente en pacientes con VPH de alto riesgo (84,6 %; p<0,005). En el 54,8 % de las muestras no se realizó un estudio serológico de VPH.

Conclusiones. El desarrollo de NIA está asociado con factores de riesgo como el VIH y los serotipos oncogénicos de VPH. Protocolizar el estudio de serotipos virales en muestras de condilomas podría optimizar la vigilancia en pacientes con serotipos de alto riesgo.

Palabras clave: virus del papiloma humano; condilomas acuminados; lesiones escamosas intraepiteliales; neoplasias del ano; cirugía general.

Introduction

Human papillomavirus (HPV) infection is the most common viral sexually transmitted infection (STI) worldwide [1]. Its presence is associated with risk factors such as having or having had numerous sexual partners, unprotected sex, immunosuppression, men who have sex with men (MSM), HIV infection and other STIs. Smoking significantly contributes to HPV persistence and dysplasia development, but does not increase the risk of acquiring HPV [1-3].

There are more than 150 HPV serotypes, classified as having low (HPV-6 and HPV-11) and high oncogenic risk (HPV-16 and HPV-18), which can cause squamous intraepithelial lesions (SIL), which are divided into low-grade (LSIL) and high-grade (HSIL). In cases resulting in anal dysplasia, the term anal intraepithelial neoplasia (AIN) is used, classified as low-grade (AIN 1) and high-grade (AIN 2 and 3) [1,2,4].

High-grade AIN is considered a precursor to anal squamous cell carcinoma (SCC), while low-grade AIN represents an active HPV infection without significant malignant potential. Thus, anal carcinoma is associated with HPV infection. Non-oncogenic serotypes are more frequently linked to the development of condyloma acuminata and low-grade SIL-1, while oncogenic serotypes can cause dysplasia and eventually cancer as they are closely related to high-grade SIL 2-3 [2,4,5].

Condyloma acuminata are exophytic papular lesions of variable size. Recurrence is common, regardless of the treatment method applied. For this reason, the prevention of the disease is of great importance and several different vaccines are available [6].

Since the implementation of preventive measures for primary HIV infection (PrEP) among at-risk population groups, there has been an increase in the incidence and prevalence of STIs, including HPV. The actual impact of preventive measures, and whether these may be associated with a higher frequency of anal dysplasia, is currently unknown [7,8].

The aim of this study was to analyse the prevalence of anatomopathological findings of anal condyloma acuminata among operated patients at a secondary care hospital, analysing risk factors, HPV genotypes and the relation with the development of AIN.

Methods

Type of study and population

A cross-sectional, descriptive study was conducted of male and female patients who had undergone surgery after a preoperative diagnosis of suspected anal condyloma acuminata at the Department of General and Digestive Surgery of a secondary care hospital between 2013 and 2023. Anatomopathological analysis of the excised tissue confirmed the diagnosis of anal condyloma acuminata. The study excluded patients whose postoperative diagnosis did not confirm condyloma acuminata. All eligible patients during the study period who met the inclusion criteria were included in the analysis. No participants were excluded due to missing data or other reasons.

Variables

Smoking status was categorized as smoker, non-smoker, or former smoker. Former smoker was defined as an individual who had ceased smoking for at least one year prior to inclusion in the study.

Data analysis

A specific Microsoft Excel® sheet was designed to record the collected data and a descriptive analysis was carried out. The data collected were anonymized using unique identifiers. No personal data were included in the Excel database, ensuring compliance with institutional and legal privacy regulations.

The quantitative variables are presented with mean and standard deviation (SD), or median and interquartile range (IQR) where distribution is not considered normal. The results of the student's t-test and, for those without normal distribution, the Mann-Whitney U test are compared. The frequency distribution of the qualitative variables is described and compared with Pearson's X^2 test or Fisher's exact test. Statistical analysis was performed using the SPSS program (IBM SPSS Statistics for Windows, Version 22.0, IBM Corporation, Armonk, NY, 2013). Statistically significant differences are considered to be $p<0.05$ and estimations are described with a 95% confidence interval.

Results

Between 2013 and 2023, operations were performed on 124 patients for anal condyloma acuminata; of these, 92 (74.2%) were men and 32 (25.8%) women, with a mean age of 37 years (SD ± 11) and a median of 35 years. Among them, 72 (58.1%) were smokers, 38 (30.6%) were non-smokers, and 14 (11.3%) were former smokers. Regarding other cardiovascular risk factors, seven patients (5.6%) had hypertension, nine (7.3%) had dyslipidemia, and only one (0.8%) was diabetic.

Of the total sample, 32 patients (25.8%) were HIV-positive and 92 (74.2%) were HIV-negative. Additionally, ten patients (8.1%) had an immunosuppressive illness or immunosuppressive treatment other than HIV. These included chronic steroid treatment for immunological illness, the presence of neoplasia (bladder neoplasia and lymphoma) or hematological diseases (polycythemia vera).

The most frequent clinical presentation was anal lesion, palpable on self-examination among 82 patients (66.1%); 11 patients (8.9%) had anal pruritus and 31 (25%) had a clinical picture similar to subacute haemorrhoidal symptoms. While generally asymptomatic, palpable lesions can occasionally present as a clinical symptom, indicating underlying anal condylomas or potential neoplasia.

Of the sample set, 38 patients (30.6%) presented a single lesion at diagnosis and intervention, while 86 (69.4%) had several lesions. The most frequent location of lesions was in the proximal and distal perianal regions, found in 61 patients (49.2%), followed by the anal/rectal canal in 41 patients (33.1%). Twenty-two subjects (17.7%) presented lesions in both the proximal and distal perianal regions and rectum, either at diagnosis or at the time of intervention.

Fifty-four percent of patients (n=67) were treated for their first episode of condyloma while 46% (n=57) were operated on for recurrences. Of the latter, 31 patients (54%) were reoperated on less than one year after their first surgery, and 26 patients (46%) were reoperated on after at least one year from the previous surgery for a condylomatous pathology.

Regarding the concomitance of lesions in different regions, 99 patients (79.8 %) had exclusively anal condylomatous lesions, 19 patients (15.3 %) also had vulvar lesions, and six patients (4.8%) had lesions in the scrotum or penis. When grouped by sex, it was observed that 59% of women had concomitant lesions in the anus and vulvar region, while 6.5% of men with anal lesions also had lesions in the scrotal or penile region.

In analyzing associated risk factors, HIV-positive patients did not show an increased risk of concomitant lesions in the genital tract (p=0.24), multiplicity (p=0.12), or combined location in the proximal and distal perianal regions and rectum (p=0.2). There was an observed trend towards statistical significance in the relation between smoking and the location of lesions (proximal and distal perianal regions/anal canal/both) (p=0.085); 67.2% of all those with proximal and distal perianal regions lesions (41 patients) and 59.1% (13 patients) of those with lesions in both locations were smokers.

A statistically significant relation was seen between having a disease or immunosuppressive treatment other than HIV with the multiplicity of lesions and anatomical location. All immunosuppressed patients (n=10; 100%) displayed a higher risk of developing multiple lesions (p=0.028). They also presented a greater presence of associated vulvar lesions (n=4; 40%) compared to 13.2% (n=15) in non-immunosuppressed patients (p=0.047).

In the anatomopathological study, some grade of AIN was observed in 29 (23.4%) patients: 17 (13.7%) with grade I AIN; four (3.2%) with grade II AIN; three (2.4%) with grade III AIN; and five (4%) with advanced HSIL. No type of AIN was detected in 95 patients (76.6%). These findings highlight the importance of precise histopathological classification for understanding disease progression. Figure 1 illustrates the histopathological findings, including AIN I (B) and AIN III (C), along with strong p16 positivity indicative of high-risk HPV infection (D).

In the serological study, the most frequently identified HPV genotypes were 11 (low risk) and 16, 18 and 31 (high risk). The presence of virus was not recorded in 103 patients (83.1%), mainly because 68 of them (54.8%) were not analysed using a CRP test.

In relation to oncogenic risk, 13 patients (10.5%) had high-risk serotypes, and eight patients (6.5%) had only low-risk serotypes. In addition, five patients (4%) had a single serotype, while 16 (12.9%) had at least two. No serotypes were found in 35 patients (28.2%).

A higher frequency of AIN was observed in patients with HIV (37.5%; n=12) compared to seronegative patients (p=0.005), as shown in Table 1. In addition, the anatomopathological analysis of AIN showed a higher prevalence of different grades of AIN among the group of patients with HIV (p=0.007). No increased risk of AIN was observed in patients with immunosuppressive treatments or diseases other than HIV (p=0.3).

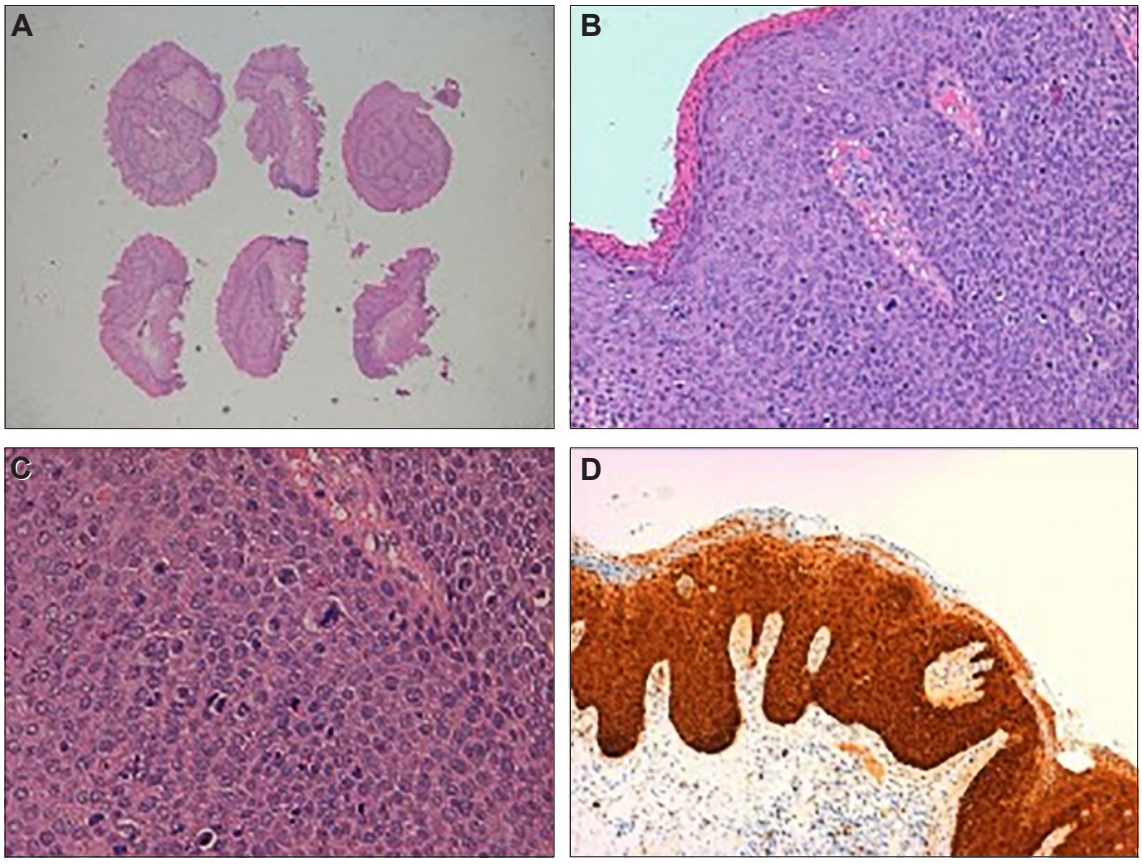

Figure 1. Histopathological and immunohistochemical analysis of condyloma acuminata lesions. **(A)** Low magnification (4x) image, Hematoxylin-Eosin stain, showing multiple fragments of hyperplastic and acanthotic squamous epithelium with elongated rete ridges. **(B)** Medium magnification (10x) Hematoxylin-Eosin stain, highlights koilocytes and viral cytopathic effects consistent with low-grade dysplasia (AIN-1). Resection margins are uninvolved. **(C)** High magnification (20x) Hematoxylin-Eosin stain, displaying severe dysplasia (AIN-3) with full-thickness epithelial atypia and numerous koilocytes. **(D)** Immunohistochemical stain for p16 (10x) shows strong nuclear and cytoplasmic positivity, confirming the presence of high-risk HPV and AIN-3.

Table 1. Relationship between human immunodeficiency viruses (HIV) infection and presence and grade of anal intraepithelial neoplasia (AIN).

	Presence of AIN					Total	p-value
	No	Yes					
HIV-	75 (81.5%)	17 (18.5%)				92 (100%)	0.005
		AIN I (LSIL)	AIN II (HSIL)	AIN III (HSIL)	Advanced HSIL		0.007
		13 (14.1%)	2 (2.2%)	0 (0,0%)	2 (2.2%)		
HIV+	20 (65.6%)	12 (37,5%)				32 (100%)	0.005
		AIN I (LSIL)	AIN II (HSIL)	AIN III (HSIL)	Advanced HSIL		0.007
		4 (12.5%)	2 (6.3%)	3 (9,4%)	3 (9.4%)		
Total	95 (76.6%)	29 (22.6%)				124 (100%)	0.005
		AIN I (LSIL)	AIN II (HSIL)	AIN III (HSIL)	Advanced HSIL		0.007
		17 (13.7%)	4 (3.2%)	3 (2.4%)	5 (4.0%)		

Source: created by the authors.

As shown in Table 2, an analysis of the relationship between the grade of AIN and the viral serotype reveals a higher frequency of neoplasia among patients with oncogenic serotypes (n=11, 84.6%; p<0.005). Some grade of AIN was also observed in 37.5% (n=3) of patients with low-risk serotypes. Notably, the majority of cases without viral detection or serological testing did not present AIN (n=88, 85.4%). However, CRP testing was not performed in 54.8% of cases, limiting the analysis. Additionally, AIN was most frequently observed as AIN I (n=17, 13.7%), followed by AIN II (n=4, 3.2%), AIN III (n=3, 2.4%), and advanced HSIL (n=5, 4.0%).

Finally, a statistically significant relation was found between the presence of AIN and oncogenic HPV serotypes, with 84.6% (n=11) of patients with high-risk serotypes presenting AIN. Among all patients, AIN was most frequently observed as AIN I (LSIL), affecting 13.7% (n=17) of the sample. High-grade AIN (HSIL) was less common but still notable, with AIN II affecting 3.2% (n=4) and AIN III affecting 2.4% (n=3). Advanced HSIL was identified in 4.0% (n=5) of cases. These findings highlight the importance of classifying AIN grades to better understand the progression of neoplasia and its correlation with viral serotypes. Simultaneous infection by two or more viral serotypes was observed but did not reach statistical significance. However, given the lack of serological testing in 54.8% of cases, further studies are needed to validate these observations.

Discussion

Condylomatous lesions are a pathology in decline since the introduction of HPV vaccinations [1,8]. However, a global prevalence of infection with any HPV is currently estimated at 31% in men, and somewhat lower in women [9]. This is particularly important since this pathology can lead to dysplasia and even anorectal neoplasia [10]. The aim of this study was to analyse the clinical characteristics of anal condylomatous lesions operated on a secondary care hospital, identifying the principal risk factors, the findings of anatomopathological analysis (presence of preneoplastic or neoplastic lesions) and their relationship to the different HPV serotypes.

Table 2. Relationship between Human papillomavirus (HPV) serotypes and presence and grade of anal intraepithelial neoplasia (AIN).

	Presence of AIN					Total	p-value
	No	Yes					
No virus or not studied	88 (85.4%)	15 (14.6%)				103 (100%)	<0.005
		AIN I (LSIL)	AIN II (HSIL)	AIN III (HSIL)	Advanced HSIL		
		10 (9.7%)	2 (1.9%)	1 (1.0%)	2 (1.9%)		
High-risk serotype	2 (15.4%)	**11 (84.6%)**				13 (100%)	
		AIN I (LSIL)	AIN II (HSIL)	AIN III (HSIL)	Advanced HSIL		
		5 (38.5%)	**2 (15.4%)**	**2 (15.4%)**	**2 (15.4%)**		
No high-risk serotype	5 (62.5%)	3 (37,5%)				8 (100%)	
		AIN I (LSIL)	AIN II (HSIL)	AIN III (HSIL)	Advanced HSIL		
		2 (25.0%)	0 (0.0%)	0 (0.0%)	1 (12.5%)		
Total	95 (76.6%)	29 (23.4%)				124 (100%)	
		AIN I (LSIL)	AIN II (HSIL)	AIN III (HSIL)	Advanced HSIL		
		17 (13.7%)	4 (3.2%)	3 (2.4%)	5 (4.0%)		

Source: created by the authors.

Incidence in men and self-examination

A higher incidence of condylomas was observed among men (74%) compared to women (25.8%), in line with the findings of previous studies [10]. Most of the patients (66.1%) sought medical treatment for self-examined palpable anal lesions. These lesions are most often described in literature as asymptomatic [1,2,6], which underscores the importance of self-examination for early detection of lesions.

Location of lesions

The most frequent location of lesions was the proximal and distal perianal regions (49.2%). However, it was observed that a significant percentage of patients (17.7%) also presented, either at diagnosis or at the time of intervention, concomitant lesions in the anal canal. Given this high incidence, preoperative endoscopic exploration or rectal examination during the surgical procedure is recommended, as proposed in the studies by Jochum et al. [11] and Kosmidis et al. [3], who highlight the importance of performing such examination for these patients, especially if there is higher risk of anal neoplasia.

Risk factors

Smoking was identified as a significant risk factor, with 58.1% of smokers in the sample. Although statistical significance was not reached for the association between smoking and the combined location of lesions, the observed trend suggests that a larger sample size may confirm this relationship. There are numerous studies that have identified smoking as a risk factor, both for condylomas acuminata and for developing dysplasia and neoplasia [5,10]. Recent studies link HPV to nasopharyngeal warts and laryngeal papillomatosis in surgeons using CO_2 and Nd:YAG lasers [12].

Recurrence of lesions

Recurrence of lesions was high (46%), which is in line with the results of previous studies [1]. In addition, a high rate of concomitant lesions in the genital area was observed among women (59%). A study by Simpson Jr et al. [10] found an association between post-defecation hygiene practices and the development of HPV-related anal lesions among women with a previous diagnosis of gynaecological lesions. The latter, associated with sexual practices, could explain the high prevalence.

HIV association, HPV and AIN serotypes

We observed a statistically significant higher incidence of NAs in patients with a previous diagnosis of HIV (37.5%), especially high-grade or carcinoma. A study by Méndez-Martínez et al. found an association despite infection control with antiretroviral therapy [13]. Another risk factor associated with the development of condyloma acuminata is immunosuppression due to disease other than HIV infection or chronic treatments such as with steroids. This association was found in the present study and in previously published research [2,3,6]. However, no relationship was identified between such immunosuppression and increased risk of developing AIN.

Lastly, a statistically significant relation was found between some grade of AIN and the presence of oncogenic HPV serotypes; simultaneous infection by two or more viral serotypes was also found but not statistically significant. However, although these findings are in line with existing literature [13], in our study the majority of samples sent for anatomopathological testing did not include the viral serological analysis. Analysis of the viral genotype in all condyloma samples is not yet protocolised, although testing has increased since 2020, especially in the presence of AIN. We can therefore consider these results to be suboptimal. It would be necessary to expand and protocolise viral serotype analysis for all patients in order to reach firm conclusions. This would also serve to support the close monitoring of patients with oncogenic serotypes, due to their greater association with the development of AIN.

Limitations

This study presents certain limitations. Given the retrospective nature of the study, and the fact that the information was collected only from electro-

nic medical records, certain risk factors widely established in literature [3,10,14] were not commonly reflected in the medical histories and thus were not included as variables. These include sexual orientation, sexual practices, the number of sexual partners and high-risk sexual relationships. The retrospective nature of the study may introduce selection bias due to loss of follow-up. No serological analysis was performed in 54.8% of patients, introducing information bias. In addition, the absence of a protocol for the analysis of HPV serotypes in anatomopathological samples inhibits a more extensive analysis of its relationship to AIN or co-infection by several serotypes. The results of this study are based on a population treated in a tertiary care hospital, which may limit their generalisability to other healthcare settings, such as primary care or community clinics.

However, it is necessary to conduct studies using multiple centers in order to improve the statistical weight of the results and justify these recommendations with a greater weight of evidence.

Conclusions

The development of anal intraepithelial neoplasia (AIN) is significantly associated with risk factors such as HIV infection and the presence of oncogenic HPV serotypes. Our study highlights the need for intensified surveillance of patients with HIV, given the high prevalence of AIN in this population. In addition, the strong association between high-risk HPV serotypes and the incidence of neoplasms underscores the importance of HPV typing in the management of condyloma acuminata. Expanding the analysis of viral serotypes in condyloma acuminata samples could guide future strategies for surveillance and management, particularly for patients with high-risk serotypes.

Compliance with ethical standards

Informed consent: This study was approved by the Hospital Research Committee and was conducted in adherence to the Declaration of Helsinki of the World Medical Association (WMA). The anonymity and the privacy of patient data was safeguarded in accordance with the Personal Data Protection and Digital Rights Act. The informed consent of patients was not requested.

Conflicts of interest: The authors declare no conflicts of interest.

Use of Artificial Intelligence: We declare that this study has been carried out and manuscript has been prepared with no use of Artificial Intelligence.

Funding: This study received no external funding.

Author's contribution:

- Conception and design of the study: Javier O. Dagnesses-Fonseca.
- Acquisition of data: Justyna Drewniak-Jakubowska.
- Data analysis and interpretation: Ainara Herrero-Mirón, Telma Meizoso-Latova, David García-Teruel.
- Drafting the manuscript: Javier O. Dagnesses-Fonseca, Ana Montané-Peruzzo
- Critical review and final approval: Telma Meizoso-Latova, David García-Teruel, Adelino Patricio Pérez-Morera, Javier Páramo-Zunzunegui.

References

1 Plotzker RE, Vaidya A, Pokharel U, Stier EA. Sexually transmitted human papillomavirus. *Infect Dis Clin North Am*. 2023;37:289-310. https://doi.org/10.1016/j.idc.2023.02.008

2 Limoges-Gonzalez M, Al-Juburi A. Anal intraepithelial neoplasia. *J Clin Gastroenterol*. 2017;51:203-7. https://doi.org/10.1097/MCG.0000000000000721

3 Kosmidis C, Sevva C, Magra V, Varsamis N, Koulouris C, Charalampous I, et al. HPV-induced anal and peri-anal neoplasia, a surgeon's experience: 5-year case series. *Diagnostics (Basel)*. 2023;13:702. https://doi.org/10.3390/diagnostics13040702

4 Vyas M, Gonzalez RS. Anal intraepithelial neoplasia: a review of terminology, differential diagnoses, and patient management. *Hum Pathol*. 2023;132:56-64. https://doi.org/10.1016/j.humpath.2022.07.005

5 Arnold JD, Byrne ME, Monroe AK, Abbott SE. The risk of anal carcinoma after anogenital warts in adults living with HIV. *JAMA Dermatol*. 2021;157:283-9. https://doi.org/10.1001/jamadermatol.2020.5252

6 Bonnez W. Papilomavirus. En: Mandell, Douglas y Bennett, editores. *Principles and practice of infectious diseases*. 9ª ed, Barcelona: Elsevier; 2020. p. 1916-1930.

7 Werner RN, Westfechtel L, Dressler C, Nast A. Anogenital warts and other HPV-associated anogenital lesions in the HIV-positive patient: a systematic review and meta-analysis of the efficacy and safety of interventions assessed in controlled clinical trials. *Sex Transm Infect*. 2017;93:543-50. https://doi.org/10.1136/sextrans-2016-053035

8 Del Romero J, Moreno-Guillén S, Rodríguez-Artalejo F, Ruiz-Galiana J, Cantón R, De Lucas-Ramos P, et al. Sexually transmitted infections in Spain: Current status. *Rev Esp Quimioter*. 2023;36:444-65.

9 World Health Organization. One in three men worldwide are infected with genital human papillomavirus. Ginebra: WHO; 2023. Cited: 2025 Mar 20. Available at: https://www.who.int/news/item/01-09-2023-one-in-three-men-worldwide-are-infected-with-genital-human-papillomavirus

10 Simpson S, Blomfield P, Cornall A, Tabrizi SN, Blizzard L, Turner R. Front-to-back & dabbing wiping behaviour post-toilet associated with anal neoplasia & HR-HPV carriage in women with previous HPV-mediated gynaecological neoplasia. Cancer Epidemiol. 2016;42:124-32. https://doi.org/10.1016/j.canep.2016.04.001

11 Jochum SB, Tian W, Goczalk MG, Ritz EM, Favuzza J, Govekar HR, Bhama AR, Saclarides TJ, Jakate S, Hayden DM. Exophytic condyloma: are they as benign as we think? *Colorectal Dis.* 2020;22:1577-84. https://doi.org/10.1111/codi.15187

12 Humo Ramos-De la Medina A, Salgado-Nesme N. El humo del electrocauterio, el riesgo olvidado y minimizado de la electrocirugía. *Rev Colomb Cir.* 2021;36:380-5. https://doi.org/10.30944/20117582.2461

13 Méndez-Martínez R, Rivera-Martínez NE, Crabtree-Ramírez B, Sierra-Madero JG, Caro-Vega Y, Galván SC, et al. Multiple human papillomavirus infections are highly prevalent in the anal canal of human immunodeficiency virus-positive men who have sex with men. BMC Infect Dis. 2014;14:671. https://doi.org/10.1186/s12879-014-0671-4

14 Oliveros-Wilches R, Rey-León C, Olarte H, Villamizar J, Acosta M, Valbuena J, et al. Carcinoma del ano: experiencia con 82 pacientes. *Rev Colomb Cir*. 1990;5:139-46.