Rev Colomb Cir. 2026;41:173-5
https://doi.org/10.30944/20117582.3051

IMAGES IN SURGERY

# Abdominal wall leiomyoma: A common tumor in an unusual location

## Leiomioma de pared abdominal: tumor frecuente en localización inusual

César Enrique Mendivil-Silva, MD

Department of Radiology, Ecocenter, Cartagena de Indias, Colombia.

Uterine fibroids, also known as leiomyomas, are benign smooth muscle tumors that frequently occur in women under the age of 50, with an incidence ranging from 20% to 70%, depending on the literature consulted [1,2]. The presence of a leiomyoma in the anterior abdominal wall—occurring as a complication following a myomectomy—accounts for less than 1% of cases [3-5]. The imaging appearance is pathognomonic and allows for appropriate contextualization.

We present the case of a 43-year-old female patient who reported a sensation of a mass for three years, with a subjective perception of growth over the preceding six months, and without pain or other associated symptoms. Of note in her medical history, at age 38, she underwent laparoscopic myomectomy without complications. An abdominal MRI was performed, which reported a solid, oval, and well-defined lesion situated between the right internal and external oblique muscles (Figure 1), showing signal intensity equivalent to that of uterine smooth muscle across various sequences. As a complementary measure, the abdominal wall was examined via ultrasound, confirming the presence of a solid, well-defined, and hypoechoic lesion with predominantly peripheral Doppler enhancement, showing no infiltration of the surrounding musculature and no communication with the peritoneal cavity (Figures 2 and 3).

Based on the diagnostic imaging reports—coupled with a long-standing clinical presentation suggestive of benign pathology—the patient underwent surgical resection of the tumor; the diagnosis of an anterior abdominal wall leiomyoma was subsequently confirmed via histology.

**Keywords:** leiomyoma; abdominal wall; ultrasound; smooth muscles.

**Palabras clave:** leiomioma; pared abdominal; ultrasonido; músculo liso; músculos abdominales.

Received: 8/29/2025 - Accepted: 9/10/2025 - Published online: 11/13/2025
Corresponding author: César Enrique Mendivil-Silva, Carrera 12 # 5A-09, Edificio Ponce de León, Apt 1802, Cartagena de Indias, Colombia. Tel.: +57 3137424548. E-mail: cesarmendivil1990@gmail.com
Cite as: Mendivil-Silva CE. Leiomioma de pared abdominal, tumor frecuente en localización inusual. Rev Colomb Cir. 2026;41:173-5. https://doi.org/10.30944/20117582.3051

This is an open Access under a Creative Commons License - BY-NC-ND https://creativecommons.org/licenses/by-ncnd/4.0/deed.es



**Figure 1.** Axial magnetic resonance image obtained using a T2-weighted sequence, demonstrating a solid mass (white arrow) with intermediate signal intensity, situated between the fibers of the internal and external oblique muscles (yellow arrows). Note the absence of communication with the peritoneal cavity.

Source: Author.

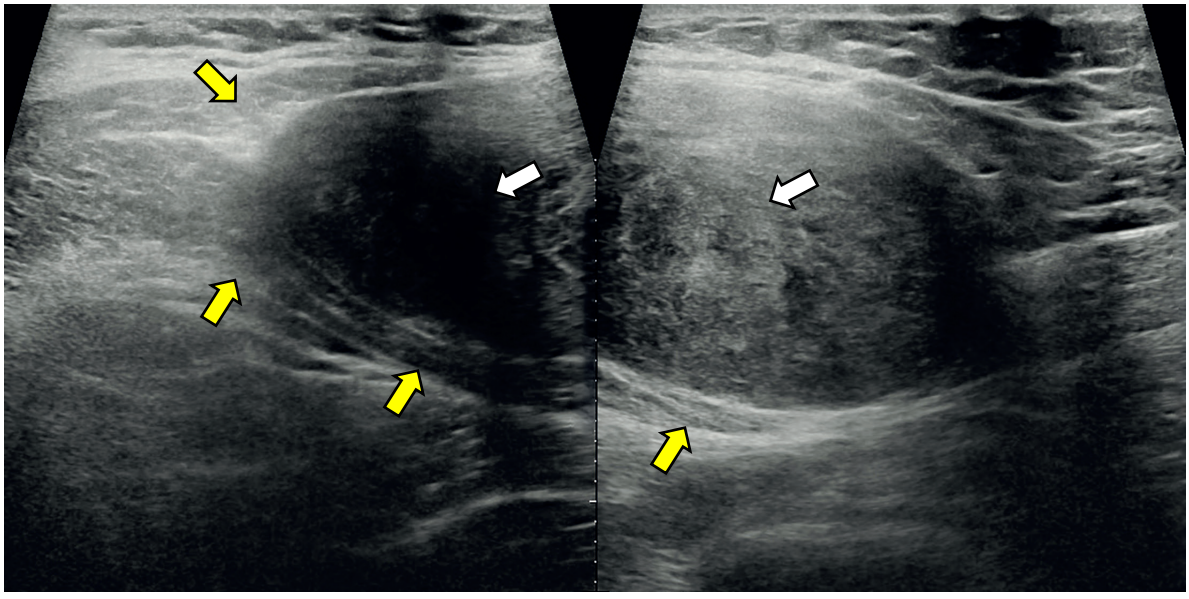

**Figure 2.** Examination of the abdominal wall using a high-frequency linear transducer, which more clearly illustrates the location of the mass (white arrows) situated within the oblique musculature of the abdominal wall (yellow arrows). A benign nature is suspected, given the well-defined margins of the lesion.

Source: Author.

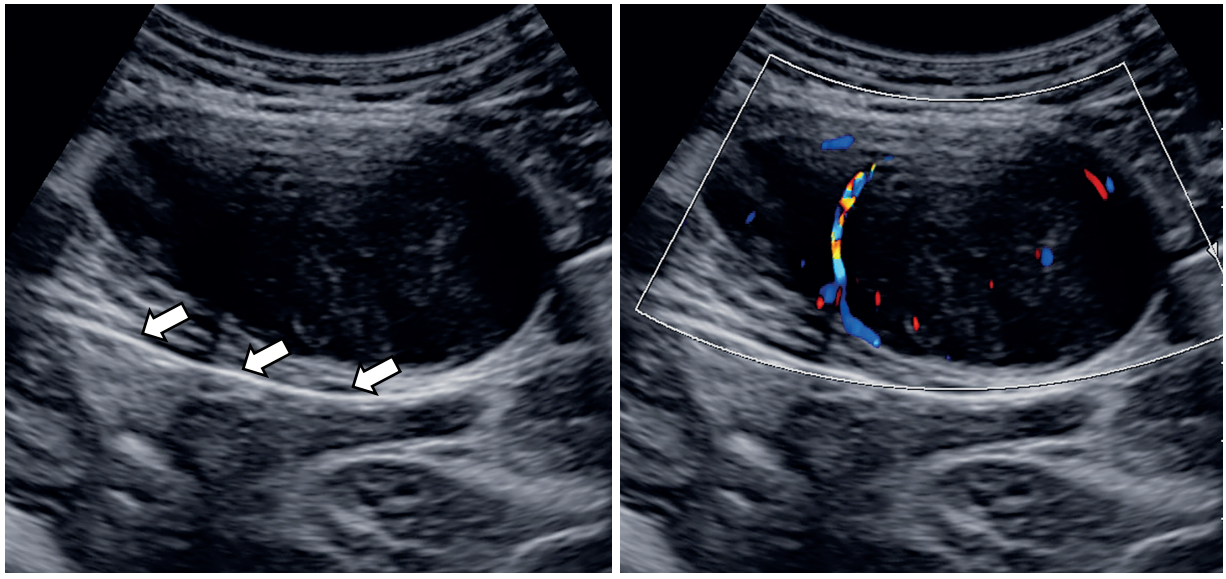

**Figure 3.** Using a convex transducer, the intact, bright echogenic line of the parietal peritoneum is visible (arrows). In the image on the right, ring-like vascularization, typical of leiomyomas, is confirmed.

Source: Author.

## Compliance with ethical standards

**Informed consent:** Informed consent was obtained from the patient for the publication of the images, safeguarding her right to confidentiality.

**Conflicts of interest:** The author declared no conflicts of interest.

**Use of Artificial Intelligence:** The author declared that artificial intelligence (AI) was not used for the writing or generation of images in the present manuscript.

**Funding:** Self-funded by the author.

## References

1 Stewart EA. Uterine fibroids. Lancet. 2001;357:293-8. https://doi.org/10.1016/S0140-6736(00)03622-9

2 Oliva E. Practical issues in uterine pathology from banal to bewildering: The remarkable spectrum of smooth muscle neoplasia. Mod Pathol. 2016;29(Suppl 1):S104-20. https://doi.org/10.1038/modpathol.2015.139

3 Moon HS, Koo JS, Park SH, Park GS, Choi JG, Kim SG. Parasitic leiomyoma in the abdominal wall after laparoscopic myomectomy. Fertil Steril. 2008;90: 1201e1-e2.

https://doi.org/10.1016/j.fertnstert.2007.08.068

4 Gianella L, Paganelli S, Sabbioni L, Cerami LB. Parasitic abdominal wall leiomyoma after open myomectomy. Clin Exp Obstet Gynecol. 2019;46:825-7. https://doi.org/10.12891/ceog5033.2019

5 Ángel-Cano G, Castro-Solis J, Arango-Martínez A. Leio-miomatosis parásita en Medellín, Colombia: Reporte de un caso y revisión de la literatura. Rev Colomb Obstet Ginecol. 2014;65:179-82. https://doi.org/10.18597/rcog.66