Rev Colomb Cir. 2026;41:1201-9
https://doi.org/10.30944/20117582.3253

ORIGINAL ARTICLE

Evaluation of targeted axillary lymph node dissection in node positive breast cancer patients post neoadjuvant therapy

Evaluación de la disección selectiva de ganglios linfáticos axilares en pacientes con cáncer de mama y afectación ganglionar tras tratamiento neoadyuvante

Mohamed A. Rizk, MD, Omar Abdelnasser Mahmoud, MD, Diaa Eldeen Saber Ahmed, MD

Department of Surgery, School of Medicine, Assiut University, Assiut, Egypt.

Abstract

Introduction. Targeted axillary dissection (TAD) removes a previously marked lymph node to improve axillary staging accuracy while potentially reducing the need for more extensive surgery and lowering postoperative morbidity. This study evaluated TAD in node-positive breast cancer (BC) patients after neoadjuvant therapy.

Methods. This prospective study included 60 patients with invasive BC and axillary metastasis. Patients underwent triple assessment, biopsy, clipping of nodes, and neoadjuvant chemotherapy (NACT) tailored to tumor subtype. Surgical management involved breast surgery with sentinel lymph node biopsy and TAD. Outcomes assessed included diagnostic accuracy, postoperative complications, and treatment response.

Results. In this study of 60 BC patients, 20% had hypertension, 21.7% had diabetes, and 26.7% had a family history. Most tumors were right-sided (55%), single (81.7%), and invasive ductal carcinoma (90%). Molecular subtypes included luminal B (38.3%) and triple-negative (41.7%). Breast-conserving surgery was performed in 73.3%, with lymph node metastasis in 53.3%. TAD achieved a 98.3% localization success rate and showed 90.6% sensitivity and 89.8% accuracy, outperforming sentinel lymph node dissection (SLND) (81.3% sensitivity, 85% accuracy). Postoperative complications were minimal (6.7% lymphedema, 10% paraesthesia), and concordance between TAD and SLND was high (95%).

Conclusions. TAD demonstrates reliable diagnostic performance for axillary staging in node-positive BC patients who became negative after NACT, outperforming SLND and showing minimal short-term postoperative morbidity. It offers a less invasive alternative to axillary lymph node dissection when combined with dual localization and

Received: 04/03/2026 - Accepted: 06/08/2026 - Published online: 10/19/2026
Corresponding author: Mohamed A. Rizk, MD. School of Medicine, Assiut University, Allopa Street, Nile Plaza Towers, Assiut, 71525, Egypt. Tel.: +20 1061988555. E-mail: med.rizk88@med.edu.eg
Cite as: Rizk MA, Mahmoud OA, Ahmed DES. Evaluation of targeted axillary lymph node dissection in node positive breast cancer patients post neoadjuvant therapy. Rev Colomb Cir. 2026;41:1201-9. https://doi.org/. https://doi.org/10.30944/20117582.3253

This is an open Access under a Creative Commons License - BY-NC-ND https://creativecommons.org/licenses/by-ncnd/4.0/deed.es

imaging. Larger, multicenter studies with longer follow-up are recommended to confirm long-term safety and validate patient selection criteria.

Keywords: breast cancer; neoadjuvant chemotherapy; sentinel lymph node; human epidermal growth factor receptor 2; histopathology.

Resumen

Introducción. La disección axilar dirigida (DAD) consiste en extirpar un ganglio linfático previamente marcado para mejorar la precisión de la estadificación axilar, reducir la necesidad de cirugías extensas y disminuir la morbilidad posoperatoria. Este estudio evaluó la DAD en pacientes con cáncer de mama (CM) y afectación ganglionar tras tratamiento neoadyuvante.

Métodos. Estudio prospectivo de 60 pacientes con CM invasivo y metástasis axilar. Se realizó una triple evaluación, biopsia, colocación de clips ganglionares y quimioterapia neoadyuvante (QTNA) según el subtipo tumoral. El tratamiento quirúrgico incluyó cirugía mamaria, biopsia del ganglio centinela (BGC) y DAD. Se evaluaron la precisión diagnóstica, las complicaciones posoperatorias y la respuesta al tratamiento.

Resultados. El 20 % presentó hipertensión, 21,7 % diabetes y 26,7 % antecedentes familiares. La mayoría de los tumores fueron derechos (55 %), únicos (81,7 %) y carcinomas ductales infiltrantes (90 %). Los subtipos más frecuentes fueron el luminal B (38,3 %) y el triple negativo (41,7 %). Se realizó cirugía conservadora en el 73,3 % de los pacientes y se observó metástasis ganglionar en 53,3 %. La DAD alcanzó un éxito de localización del 98,3 % (sensibilidad 90,6 % y precisión 89,8 %) versus la BGC (81,3 % y 85 %, respectivamente). Las complicaciones fueron mínimas: linfedema (6,7 %) y parestesia (10 %). La concordancia entre DAD y BGC fue del 95 %.

Conclusiones. La DAD mostró un rendimiento diagnóstico fiable en pacientes con afectación ganglionar inicial que negativizaron tras QTNA, superando a la BGC y con mínima morbilidad a corto plazo. Puede constituir una alternativa menos invasiva a la disección axilar completa. Se requieren estudios multicéntricos y seguimiento prolongado para confirmar su seguridad y validar la selección de pacientes.

Palabras clave: cáncer de mama; quimioterapia neoadyuvante; ganglio centinela; receptor 2 del factor de crecimiento epidérmico humano; histopatología.

Introduction

Breast cancer (BC) is the most frequently diagnosed malignancy among women globally, with an estimated 2.3 million new cases and over 685,000 deaths annually. While curative outcomes are achievable in 70–80% of patients presenting with early-stage, non-metastatic disease, advanced BC with distant organ spread remains largely incurable with contemporary therapies. Also, BC is the most diagnosed neoplasm worldwide, regardless of the degree of national development, according to GLOBOCAN reports for 2022 [1]. In higher-income regions, early detection is more common, leading to better prognosis, whereas in resource-limited settings, diagnoses often occur at later stages, resulting in poorer survival outcomes [2,3].

For patients with node-positive disease, the axillary lymph node status is the single most important prognostic factor. Historically, axillary lymph node dissection (ALND) was the standard surgical approach for staging and achieving locoregional control. However, due to its association with significant morbidity, including lymphedema and sensory deficits, the paradigm has shifted toward less invasive techniques. Sentinel lymph node biopsy (SLNB) became the standard for clinically node-negative patients, offering accurate staging with minimal morbidity [4].

The widespread adoption of neoadjuvant chemotherapy (NACT) has further affected axillary management. NACT can eradicate disease in the breast and axillary nodes, leading to a pathological

complete response (pCR) in a substantial proportion of patients, particularly those with Human Epidermal Growth Factor receptor 2 (HER2) positive and triple-negative subtypes. In patients who present with node-positive disease (cN+) but achieve a clinical complete response in the axilla (ycN0) post-NACT, the optimal surgical strategy is a subject of ongoing debate. While SLNB alone in this setting is attractive for its minimal invasiveness, prospective trials have demonstrated unacceptably high false-negative rates (FNRs) of 12–14% [4]. Despite its promising accuracy, the long-term oncological outcomes of relying solely on TAD for axillary staging in this patient population require further validation through studies with robust clinical outcomes.

Therefore, the aim of this study was to evaluate the diagnostic accuracy and short-term safety of targeted ALND in node-positive BC patients following neoadjuvant therapy to avoid the high false-negative rates (FNRs) of sentinel lymph node dissection (SLND) after NACT and the morbidity of ALND.

Methods

This is a combined prospective and retrospective interventional study that was conducted on 60 female patients diagnosed with proven invasive BC, axillary metastasis with staging between N1 and N2, without distant metastasis, and complete axillary response to neoadjuvant therapy confirmed by clinical and radiological assessment.

Exclusion criteria included patients ineligible for NACT, those with residual positive axillary nodes following therapy, patients with distant metastasis, or those with axillary metastasis from another primary tumor.

All participants underwent a standardized triple assessment. This included a medical history with emphasis on family, surgical, contraceptive, and hormonal background, as well as a thorough clinical breast and axillary examination. Imaging studies included high-resolution sonomammography of both breasts and lymph nodes, with MRI reserved for dense breasts or high-risk patients. Histopathological confirmation was ensured through Tru-Cut or fine-needle aspiration cytology of suspicious lesions. Clipping of primary tumors and involved axillary nodes with metallic clips was performed to aid later localization. Immunohistochemical profiling for ER, PR, HER2/neu, and Ki-67 was carried out on biopsy samples.

NACT was tailored according to BC subtypes. Standard regimens involved anthracycline-based therapy (doxorubicin/cyclophosphamide) followed by taxane-based agents. HER2-positive tumors received targeted therapies such as trastuzumab and pertuzumab. Patients with triple-negative disease, especially those deemed high-risk, were additionally administered pembrolizumab. Post-therapy reassessment with ultrasound or MRI determined treatment response and surgical eligibility.

Surgical procedure

Standard preoperative workup included laboratory investigations, anesthetic review, and localization of clipped lymph nodes via ultrasound or intraoperative radiography. Under general anesthesia, SLNB was performed following periareolar injection of patent-blue dye. Oncoplastic wide local excision or mastectomy was carried out depending on disease extent.

Targeted axillary dissection (TAD) was performed on the previously clipped nodes, guided by wires applied by ultrasonography or under intraoperative X-ray. Excised specimens underwent intraoperative radiography to confirm marker retrieval. Sentinel and clipped nodes were examined via frozen section. Excised lymph nodes were examined by experienced breast pathologists. Pathological assessment was performed independently. Although the presence of a metallic clip could not be concealed, pathologists were not informed of the intraoperative TAD or SLND findings. Formal axillary clearance was performed if more than two nodes showed residual metastases (Figure 1).

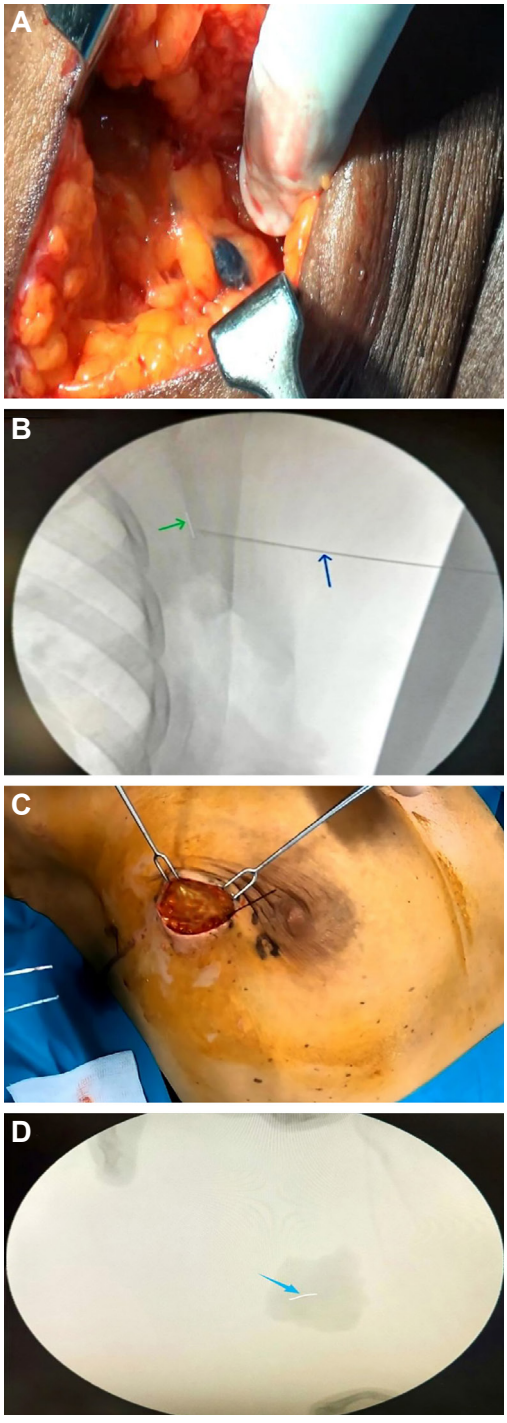

Figure 1. (A) Sentinel axillary lymph node intraoperative. **(B)** Wire localization of clipped node under C-arm screening (blue arrow pointing to the wire and green arrow pointing to the clip). **(C)** Breast conservative surgery with targeted axillary dissection by wire guidance. **(D)** Confirmation of clip in excised node using intraoperative x- ray before sending to histopathology (blue arrow pointing to the clip).

Source: Authors' own elaboration.

Follow-up and outcomes

Patients were monitored postoperatively in phases, beginning with wound healing assessment and complication detection during the immediate postoperative period. Subsequent follow-up at four–six weeks included assessment of arm mobility, arm edema, and pathology review, while long-term surveillance focused on recurrence detection and therapy-related complications.

The primary outcome was the diagnostic accuracy of TAD compared with SLND in patients with node-positive BC who showed a complete nodal clinical response after NACT. Secondary outcomes assessed postoperative morbidity, including lymphedema, paresthesia, sensory loss, and hospital stay.

Statistical analysis

Statistical analysis was conducted using SPSS v26. Normality was assessed using the Shapiro–Wilk test, and data were expressed as mean ± SD for parametric data, median with interquartile range for non-parametric data, and frequency with percentage for categorical variables.

Results

Age ranged from 28 to 60 years, with a mean value (±SD) of 44 ± 8 years. Twelve (20%) patients had hypertension, 13 (21.7%) patients had diabetes mellitus, and 16 (26.7%) patients had a positive family history. The affected breast was the right in 33 (55%) patients and the left in 27 (45%) patients. The number of lesions was single in 49 (81.7%) patients and multiple in 11 (18.3%) patients. Axillary LNs were palpable in 41 (68.3%) patients and non-palpable (detected by ultrasonography) in 19 (31.7%) patients. T classification was T1 in 3 (5%) patients, T2 in 39 (65%) patients, and T3 in 18 (30%) patients. N classification was N1 in 49 (81.7%) patients and N2 in 11 (18.3%) patients. M classification was M0 in all patients. Histopathology showed invasive ductal carcinoma (IDC) in 54 (90%) patients and invasive lobular carcinoma in six (10%) patients. Molecular classification was luminal A in nine (15%) patients, luminal B in 23 (38.3%) patients, triple-negative in 25 (41.7%) patients, and HER2-neu overexpression in three

(5%) patients. Regarding operative treatment, 44 (73.3%) patients underwent breast-conserving surgery, and 16 (26.7%) patients underwent mastectomy (Table 1).

Lymph node metastasis by histopathology after surgery was positive in 32 (53.3%) patients. Final histopathology of the retrieved axillary lymph nodes was used as the reference standard; however, formal axillary clearance was not performed in all patients, which may introduce partial verification bias. Lymph node metastasis by TAD was positive in 32 (54.2%) patients. Lymph node metastasis by SLND was positive in 29 (48.3%) patients. Targeted lymph node localization failed in one (1.7%) patient, possibly related to clip migration or post-neoadjuvant fibrosis. Twelve patients underwent formal ALND; eight (66.7%) of them had positive axillary nodes, and four (33.3%) patients had no lymph node involvement (Table 2).

Concordance between TAD and SLND was observed in 57 patients (95%), with three (5%) discordant cases in which SLND was negative while TAD revealed residual nodal disease. Suction removal was performed at 7 days in 17 (28.3%) patients, 10 days in 32 (53.3%) patients, and 14 days in 11 (18.3%) patients. Hospital stays ranged from 1 to 3 days, with a mean value of 2 ± 0.5 days. Four (6.7%) patients had lymphoedema (these four patients were among the 12 patients who underwent complete axillary dissection after TAD showed more than 2 positive LNs), and six (10%) patients had paraesthesia (Table 3).

The role of TAD and SLND in predicting axillary node metastasis compared to final histopathology of retrieved axillary lymph nodes is that TAD demonstrated significant diagnostic performance in detecting axillary node metastasis ($p<0.001$; Kappa=0.800), with a sensitivity of 90.6%, specificity of 88.9%, positive predictive value (PPV) of 90.6%, negative predictive value (NPV) of 88.9%, and accuracy of 89.8%. Also, SLND can predict axillary node metastasis ($p=0.002$; Kappa=0.700), with a sensitivity of 81.3%, specificity of 89.3%, PPV of 89.7%, NPV of 80.6%, and accuracy of 85% (Table 4).

Table 1. Baseline demographic, clinical, pathological characteristics, and surgical management of the studied patients (n=60).

Variable	n (%)
Age (years), mean	44 ± 8
Comorbidities	
Hypertension	12 (20%)
Diabetes mellitus	13 (21.7%)
Family history of breast cancer	16 (26.7%)
Side of tumor	
Right	33 (55%)
Left	27 (45%)
Number of lesions	
Single	49 (81.7%)
Multicentric	11 (18.3%)
Axillary LN	
Palpable	41 (68.3%)
Not palpable	19 (31.7%)
T classification	
T1	3 (5%)
T2	39 (65%)
T3	18 (30%)
N classification	
N1	49 (81.7%)
N2	11 (18.3%)
M classification	
M0	60 (100%)
Histopathology	
Invasive ductal carcinoma	54 (90%)
Invasive lobular carcinoma	6 (10%)
Molecular classification	
Luminal A	9 (15%)
Luminal B	23 (38.3%)
Triple negative	25 (41.7%)
HER2 neu overexpression	3 (5%)
Operative treatment	
Breast conserving surgery	44 (73.3%)
Mastectomy	16 (26.7%)

Data are presented as mean ± SD or frequency (%). LN: lymph node; HER2: Human Epidermal growth factor Receptor 2.

Source: Authors' own elaboration.

Table 2. Assessment of axillary nodes after surgery of the patients studied (n=60).

Variable	n (%)
Lymph node metastasis (histopathology)	
Positive	32 (53.3)
Negative	28 (46.7)
Lymph node metastasis by TAD in successful localization cases, (n=59)	
Positive	32 (54.2)
Negative	27 (45.8)
Lymph node metastasis by SLND	
Positive	29 (48.3)
Negative	31(51.7)
Targeted LN localization	
Failed	1 (1.7)
Successful	59 (98.3)
Axillary dissection (n=12)	
Positive	8 (66.7)
Negative	4 (33.3)

Data are presented as frequency (%). TAD: targeted axillary dissection; SLND: sentinel lymph node dissection; LN: lymph node.

Source: Authors' own elaboration.

Table 3. Concordance between TAD and SLND, hospital stay, suction removal, and complications of the studied patients (n=60).

Variable	n (%)
Concordance between TAD and SLND	
Negative (discordant)	3 (5%)
Positive (concordant)	57 (95%)
Hospital stays (days)	2 ± 0.5
Suction removal	
7 days	17 (28.3%)
10 days	32 (53.3%)
14 days	11 (18.3%)
Complications	
Lymphoedema	4 (6.7%)
Paraesthesia	6 (10%)

Data are presented as mean ± SD or frequency (%). TAD: targeted axillary dissection; SLND: sentinel lymph node dissection.

Source: Authors' own elaboration.

Table 4. Role of TAD and SLND in prediction of axillary nodes metastasis compared to final histopathology.

Method	Histopathology Yes	Histopathology No	p-value	Kappa	Sensitivity (%)	Specificity (%)	PPV (%)	NPV (%)	Accuracy (%)
TAD (n=59)									
Yes	29 True positive	3 False positive	<0.001*	0.800	90.6%	88.9%	90.6%	88.9%	89.8%
No	3 False negative	24 True negative							
SLND (n=60)									
Yes	26 True positive	3 False positive	0.002*	0.700	81.3%	89.3%	89.7%	80.6%	85.0%
No	6 False negative	25 True negative							

Data are presented as frequencies (%) and percentages where indicated. *: Significant p<0.05; TAD: targeted axillary dissection; SLND: sentinel lymph node dissection; PPV: Positive Predictive Value; NPV: Negative Predictive Value.

Source: Authors' own elaboration.

Discussion

TAD has emerged as a promising technique in the surgical management of node-positive BC patients who achieve complete nodal downstaging following NACT [5]. By combining SLND with excision of a clipped metastatic node, TAD improves the accuracy of axillary staging while potentially sparing patients the morbidity of ALND [6]. In this study, we assessed the efficacy of TAD in predicting axillary lymph node status in a cohort of 60 patients with initially node-positive BC treated with NACT.

Our patient population reflected tumor and nodal distributions similar to those in previously published series [7]. Most cases were T2 and N1 at diagnosis (65% and 81.7%, respectively), with IDC comprising the predominant histological subtype [7]. This aligns with Sedky et al. [8], who also reported IDC in 88% of an Egyptian cohort. Molecular subtyping revealed a predominance of luminal B and triple-negative tumors, which was consistent with global data showing that these subtypes were strongly represented in node-positive patients undergoing NACT [9].

Surgical management demonstrated a high rate of breast-conserving surgery (BCS) in our series (73.3%), paralleling findings from Mamtani et al. [10], who noted increasing utilization of BCS after NACT [9]. Large analyses confirm that NACT facilitates tumor downstaging and expands eligibility for BCS, particularly in triple-negative and HER2-positive subgroups.

Our findings support the growing evidence for TAD as an accurate technique for axillary staging post-NACT [5]. TAD identified lymph node metastases in 54.2% of patients, with a sensitivity of 90.6%, specificity of 88.9%, and overall accuracy of 89.8% [11]. The FNR was 9.4%, lower than that reported for SLND alone (18.7% in our series). These results were consistent with Caudle et al. [5], who demonstrated superior accuracy of TAD compared to SLND.

Three false-positive results were observed, potentially attributable to the detection of isolated tumor cells or micrometastases within the targeted or sentinel lymph nodes. These observations were consistent with previously reported patterns of low-volume nodal involvement in similar cohorts [5].

Similarly, the ACOSOG Z1071 trial highlighted the limitations of SLND in previously node-positive patients, with an FNR exceeding the acceptable threshold, particularly when the clipped node was not retrieved [12]. Our study also underscores the critical role of meticulous preoperative localization, as concordance between the clipped node and sentinel node reached 95%, comparable with results from other series [13,14].

Notably, our study demonstrated that TAD was more reliable than SLND in detecting residual nodal disease, with fewer false negatives. This emphasizes its prognostic significance, particularly given that nodal involvement remains a critical factor in guiding adjuvant systemic and radiation therapy [15]. In line with Galimberti et al. [11], our data demonstrated that TAD offers not only diagnostic accuracy but also favorable long-term implications for treatment planning through refined axillary staging.

Complications in our cohort were few, with lymphoedema observed in 6.7% of cases and paraesthesia in 10%. These rates were lower than those typically reported with ALND, reaffirming the role of TAD as a less morbid alternative for appropriately selected patients [16].

This study was limited by its small sample size (n=60) and the absence of a robust control group (partial ALND confirmation in only 12 patients). Complete blinding of pathologists was not feasible due to the presence of metallic clips inherent to the TAD technique, which may have introduced observer bias. However, this limitation reflects real-world surgical practice.

Technical challenges included a small number of false-positive results, potentially related to micrometastatic disease or histopathological interpretation variability.

Based on the outcomes, TAD is recommended as a feasible alternative for axillary staging in biopsy-confirmed node-positive patients who respond to NACT. Integrating dual localization methods (wire guidance and blue dye), intraoperative imaging, and specimen X-ray further improves retrieval accuracy. To strengthen these results, large-scale multicenter studies with extended follow-up are essential to validate long-term oncological outcomes, refine patient selection, and determine the procedure's long-term impact on recurrence and survival outcomes.

Conclusions

This study establishes TAD as an accurate and effective method for ALN evaluation in patients with node-positive BC following NACT. TAD

demonstrated high diagnostic performance, achieving 90.6% sensitivity, 88.9% specificity, and 89.8% accuracy, closely matching final histopathological outcomes. It outperformed SLND, which showed slightly lower sensitivity (81.3%) and accuracy (85%). Moreover, TAD achieved a 95% success rate in targeted node localization and was associated with minimal postoperative complications. Despite limitations, including a small cohort size and the absence of routine ALND for pathological confirmation, the results align with international evidence supporting TAD as a reliable staging tool. These findings highlight TAD's potential to reduce the need for ALND, thereby lowering complication risks.

Compliance with ethical standards

Informed consent: The study was conducted after approval from the Ethical Committee of Assiut University Hospitals, Assiut, Egypt (approval code: 04-2023-200073) at 31/1/2023. A written informed consent was obtained from the patients.

Conflicts of interest: The authors declare that they have no conflicts of interest.

Use of Artificial Intelligence: The authors declare that no artificial intelligence–assisted technologies were used during the development of the project.

Funding: This study was conducted without external funding.

Author's contributions:

- Study design and conception: Mohamed A. Rizk, Omar Abdelnasser Mahmoud, Diaa Eldeen Saber Ahmed.
- Data acquisition: Omar Abdelnasser Mahmoud, Diaa Eldeen Saber Ahmed.
- Data analysis and interpretation: Omar Abdelnasser Mahmoud, Diaa Eldeen Saber Ahmed.
- Manuscript drafting: Mohamed A. Rizk.
- Critical review and final approval: Mohamed A. Rizk, Omar Abdelnasser Mahmoud, Diaa Eldeen Saber Ahmed.

References

1 Díaz-Casas SE, Rosero-Díazdel Castillo FJ, Mendoza-Díaz S, Sáenz-Ladino A, Sánchez-Pedraza R, Silva-Cárdenas SP, et al. Oncologic Outcomes of Breast-Conserving Surgery in a Colombian Cancer Center: An Observational, Analytical, Retrospective Cohort Study. Cancers. 2025;17:1131. https://doi.org/https://doi.org/10.3390/cancers17071131

2 Sung H, Ferlay J, Siegel RL, Laversanne M, Soerjomataram I, Jemal A, et al. Global Cancer Statistics 2020: GLOBOCAN Estimates of Incidence and Mortality Worldwide for 36 Cancers in 185 Countries. CA Cancer J Clin. 2021;71:209-49. https://doi.org/10.3322/caac.21660

3 Allemani C, Weir HK, Carreira H, Harewood R, Spika D, Wang XS, et al. Global surveillance of cancer survival 1995-2009: analysis of individual data for 25,676,887 patients from 279 population-based registries in 67 countries (CONCORD-2). Lancet. 2015;385:977-1010. https://doi.org/10.1016/s0140-6736(14)62038-9

4 Banys-Paluchowski M, Gruber IV, Hartkopf A, Paluchowski P, Krawczyk N, Marx M, et al. Axillary ultrasound for prediction of response to neoadjuvant therapy in the context of surgical strategies to axillary dissection in primary breast cancer: a systematic review of the current literature. Arch Gynecol Obstet. 2020;301:341-53. https://doi.org/10.1007/s00404-019-05428-x

5 Caudle AS, Yang WT, Krishnamurthy S, Mittendorf EA, Black DM, Gilcrease MZ, et al. Improved Axillary Evaluation Following Neoadjuvant Therapy for Patients With Node-Positive Breast Cancer Using Selective Evaluation of Clipped Nodes: Implementation of Targeted Axillary Dissection. J Clin Oncol. 2016;34:1072-8. https://doi.org/10.1200/jco.2015.64.0094

6 Alamoodi M, Wazir U, Sakr RA, Venkataraman J, Mokbel K, Mokbel K. Evaluating magnetic seed localization in targeted axillary dissection for node-positive early breast cancer patients receiving neoadjuvant systemic therapy: a comprehensive review and pooled analysis. J Clin Med. 2024;13:2908. https://doi.org/https://doi.org/10.3390/jcm13102908

7 Ahmed M, Douek M. Targeted axillary dissection after neoadjuvant therapy in breast cancer. Br J Surg. 2018;105:313-4. https://doi.org/10.1002/bjs.10626

8 Sedky MK, Mostafa AA, AboElazm HA, Zaid MH. Evaluation of targeted axillary dissection in node positive locally advanced breast cancer patients with complete pathological response to neoadjuvant chemotherapy. Egypt J Surg. 2024;43:105. https://doi.org/https://doi.org/10.4103/ejs.ejs_292_23

9 Al-Thoubaity FK. Molecular classification of breast cancer: A retrospective cohort study. Ann Med Surg (Lond). 2020;49:44-8. https://doi.org/10.1016/j.amsu.2019.11.021

10 Mamtani A, Nakhlis F, Downs-Canner S, Zabor EC, Morrow M, King TA, et al. Impact of Age on Locoregional and Distant Recurrence After Mastectomy for Ductal Carcinoma In Situ With or Without Microinvasion. Ann Surg Oncol. 2019;26:4264-71. https://doi.org/10.1245/s10434-019-07693-1

11 Galimberti V, Cole BF, Zurrida S, Viale G, Luini A, Veronesi P, et al. Axillary dissection versus no axillary dissection in patients with sentinel-node micrometastases (IBCSG 23-01): a phase 3 randomised controlled trial. Lancet Oncol. 2013;14:297-305. https://doi.org/10.1016/s1470-2045(13)70035-4

12 Boughey JC, Ballman KV, Le-Petross HT, McCall LM, Mittendorf EA, Ahrendt GM, et al. Identification and Resection of Clipped Node Decreases the False-negative Rate of Sentinel Lymph Node Surgery in Patients Presenting With Node-positive Breast Cancer (T0-T4, N1-N2) Who Receive Neoadjuvant Chemotherapy: Results From ACOSOG Z1071 (Alliance). Ann Surg. 2016;263:802-7. https://doi.org/10.1097/sla.0000000000001375

13 Swarnkar PK, Tayeh S, Michell MJ, Mokbel K. The Evolving Role of Marked Lymph Node Biopsy (MLNB) and Targeted Axillary Dissection (TAD) after Neoadjuvant Chemotherapy (NACT) for Node-Positive Breast Cancer: Systematic Review and Pooled Analysis. Cancers (Basel). 2021;13:1539. https://doi.org/10.3390/cancers13071539

14 Martínez M, Jiménez S, Guzmán F, Fernández M, Arizaga E, Sanz C. Evaluation of Axillary Lymph Node Marking with Magseed® before and after Neoadjuvant Systemic Therapy in Breast Cancer Patients: MAGNET Study. Breast J. 2022;2022:6111907. https://doi.org/10.1155/2022/6111907

15 Hennessy BT, Hortobagyi GN, Rouzier R, Kuerer H, Sneige N, Buzdar AU, et al. Outcome after pathologic complete eradication of cytologically proven breast cancer axillary node metastases following primary chemotherapy. J Clin Oncol. 2005;23:9304-11. https://doi.org/10.1200/jco.2005.02.5023

16 He L, Qu H, Wu Q, Song Y. Lymphedema in survivors of breast cancer. Oncol Lett. 2020;19:2085-96. https://doi.org/10.3892/ol.2020.11307